

ACTA MEDICA MARTINIANA

*Journal for Biomedical Sciences,
Clinical Medicine and Nursing*

Contents

3

Influence of restraint stress on endogenous central histamine-induced antinociceptive effect in rats: Studies with histamine N-methyltransferase inhibitor SKF 91488
Jerzy Jochem, Barbara Rybus-Kalinowska, Krystyna Żwirska-Korczala

9

Surfactant lung lavage in rabbits with meconium aspiration - a pilot study
Ševcová Daniela, Čalkovská Andrea, Drgová Anna, Javorka Kamil

15

The respiratory adverse effects of enalapril and inhaled furosemide
Fraňová Soňa, Nosáľová Gabriela

20

Dermatologic tumors findings in a juvenile hyaline fibromatosis adult patient during 7-year- follow-up

Katarína Adamicová, Želmíra Fetisovová, Juraj Péc, Dagmar Statelová, Yvetta Mellová,
Hubert Poláček, Naďa Mišovicová

27

Tumors of the brachial plexus
Viktor Matejčík

*Published by the Jessenius Faculty of Medicine in Martin,
Comenius University in Bratislava, Slovakia*

Editor-in-Chief:

Javorka, K., Martin, Slovakia

International Editorial Board:

Belej, K., Martin, Slovakia

Buchanec, J., Martin, Slovakia

Honzíková, N., Brno, Czech Republic

Kliment, J., Martin, Slovakia

Lehotský, J., Martin, Slovakia

Lichnovský, V., Olomouc, Czech Republic

Mareš, J., Praha, Czech Republic

Plank, L., Martin, Slovakia

Stránsky, A., Martin, Slovakia

Tatár, M., Martin, Slovakia

Zwirska-Korczala, K., Zabrze-Katowice, Poland

Editorial Office:

Acta Medica Martiniana

Jessenius Faculty of Medicine, Comenius University

(Dept. of Physiology)

Malá Hora 4

037 54 Martin

Slovakia

Instructions for authors: <http://www.jfmed.uniba.sk> (Acta Medica Martiniana)

Tlač:

alfaPRINT. Martin

INFLUENCE OF RESTRAINT STRESS ON ENDOGENOUS CENTRAL HISTAMINE-INDUCED ANTINOCICEPTIVE EFFECT IN RATS: STUDIES WITH HISTAMINE N-METHYLTRANSFERASE INHIBITOR SKF 91488

JERZY JOCHEM, BARBARA RYBUS-KALINOWSKA, KRYSZYNA ŻWIERSKA-KORCZALA

Department of Physiology, Medical University of Silesia, Zabrze, Poland

Abstract

Histamine as a neurotransmitter participates in modulation of pain transmission within the central nervous system. Exogenous histamine administered intracerebroventricularly (*icv*) as well as endogenous histamine, after blockage of its catabolism by histamine N-methyltransferase (HNMT) inhibitors, which leads to an increase in endogenous histamine concentrations, produce an antinociceptive effect. On the other hand, there is an activation of the histaminergic system, with the increase in histamine turnover and/or release from neurones, in response to potentially dangerous stimuli disturbing homeostasis, including changes in blood pressure, dehydration and nociceptive stimuli. Therefore, the aim of the present study was to examine the influence of prior restraint immobilisation stress on HNMT inhibitor SKF 91488-induced antinociceptive effect in rats.

SKF 91488 (100 µg *icv*) produced an increase in endogenous histamine concentrations 15 min after treatment in the cerebral cortex (1.09 ± 0.11 vs. 0.61 ± 0.22 nmol/g; $p < 0.01$), hypothalamus (5.67 ± 0.64 vs. 4.11 ± 0.49 nmol/g; $p < 0.01$) and medulla oblongata (0.53 ± 0.19 vs. 0.32 ± 0.08 nmol/g; $p < 0.05$) in comparison to saline-treated group. The effect was accompanied by a dose-dependent (50-100 µg *icv*) analgesic action both in tail-flick test and paw pressure test (Randall-Selitto test). Prior restraint stress increased SKF 91488-induced effect, however, it did not change central histamine concentrations. The restraint stress alone did not influence central histamine concentrations as well as nociceptive responses.

The study confirms that SKF 91488 is an effective *in vivo* inhibitor of HNMT activity which increases endogenous central histamine concentrations, and thus produces an antinociceptive action. Moreover, prior restraint stress increases endogenous histamine-induced influence on pain transmission, possibly as a result of the activation of the histaminergic system.

Key words: endogenous histamine, pain perception, restraint stress, rat

INTRODUCTION

Histaminergic neurones which are concentrated mainly in the tuberomammillary nucleus of the posterior hypothalamus send innervation, *via* ascending and descending fibres, to almost all parts of the brain and, as postulated, may thus regulate brain activities (1, 2). Indeed, the histaminergic system influences various functions of the central nervous system, such as arousal mechanisms, fluid balance, food intake, temperature regulation, learning, cardiovascular regulation and pain perception (1, 3). The histaminergic system is especially associated with response to adverse or potentially dangerous stimuli, including dehydration, changes in blood pressure, nociceptive stimuli and other kinds of stress (1). In these conditions, there is an increase in turnover and/or release of neuronal histamine, leading to the activation of compensatory mechanisms, such as the increase in the sympathetic nervous system activity, the secretion of arginine vasopressin and proopiomelanocortin-derived peptides, including adrenocorticotrophic hormone (ACTH), β -endorphin, β -lipotropin and α -melanocyte stimulating hormone (α -MSH) (1). The role of these compensatory mechanisms is the maintenance of homeostasis, for example the increase in blood pressure and respiratory rate, or suppression of pain, which is necessary for survival (1, 4).

Previous studies demonstrate that the histaminergic system may directly influence the transmission of information from nociceptors (1, 3). Exogenous histamine administered into the brain lateral ventricle (*icv*) (5), the dorsal raphe nucleus or in the periaqueductal gray region in rats (6) evokes a dose-related antinociceptive action. Similar effects of endogenous histamine are observed after injections of metoprine, BW 301U and SKF 91488 – inhibitors of histamine N-methyl-

Address for correspondence:

Dr n. med. Jerzy Jochem, Katedra i Zakład Fizjologii, Śląska Akademia Medyczna, ul. H. Jordana 19, 41-808 Zabrze, Poland,

Phone/fax: ++48 32 272 23 62, e-mail: jjochem@poczta.onet.pl

transferase (HNMT), the enzyme catabolising histamine within neurones (7, 8). Moreover, loading with histamine precursor L-histidine, which increases central histamine concentrations, also evokes an antinociceptive effect in rats (7).

Since the histaminergic system is activated in response to adverse or potentially dangerous stimuli (1), the aim of the present study was to examine the influence of prior restraint immobilisation stress on SKF-91488-induced antinociceptive effect in male rats. Furthermore, the concentrations of endogenous histamine in the cerebral cortex, hypothalamus and medulla oblongata were measured to confirm the role of the histaminergic system activation in the antinociceptive effect.

METHODS

Male Wistar rats weighing 230-250 g (5-6 months old) were used in all experiments. The animals were housed five per cage, under controlled conditions of temperature (20-22°C), humidity (60-70%), lighting (12 h light/dark cycle) and provided with food and water *ad libitum*. All procedures were carried out according to EU directives and reviewed by local ethics committee. For *icv* treatment rats were prepared 5-7 days before the experiment by stereotaxic implantation, under ketamine/xylazine (60 mg/kg + 10 mg/kg intraperitoneally) anaesthesia, of polyethylene cannula into the right brain lateral ventricle as described previously (4). All *icv* injections were given in 5.0 µl of saline vehicle.

The antinociceptive activity was quantified using tail-flick test (9) and paw pressure test (Randall-Selitto test) (10). In the tail-flick test, the thermal stimulus from analgesimeter (Porfex, Białystok, Poland) was adjusted in preliminary studies to produce a tail-flick response in control rats within 4-6 s. Animals with higher control values were excluded. A cut-off time of 15 s was used to avoid blistering. Three tail-flick latencies, at 60 s intervals, were taken and the mean value was recorded. Paw pressure thresholds (Randall-Selitto test) were determined for the left hind paw of rats using an automated analgesimeter (Ugo Basile Biological Research Apparatus, Comerio - Varese, Italy). Rats scoring below 50 g or over 70 g before treatment were rejected. An arbitrary cut-off value of 200 g was adopted.

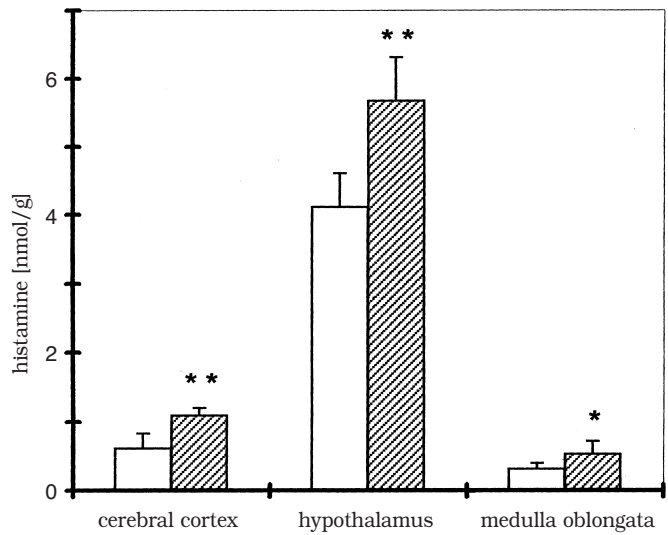
For the induction of immobilisation stress, the animals were restrained individually by putting them in a cylindrical cage for 30 min to allow only a limited degree of movement. Despite the limited movement, all the animals appeared to be in good physical condition after the restraint.

The rats were *icv* treated with SKF 91488 or saline (5 µl). Since SKF 91488 (4-[N,N-dimethylamino]butylisothiourea dihydrochloride) does not cross the blood-brain barrier, it was administered centrally. In order to measure the influence of restraint stress on pain perception, the animals were stressed in separate groups for 30 min before SKF 91488 or saline injection. The antinociceptive activities were measured before treatment and at 15, 30, 45, 60 and 120 min after *icv* administration of SKF 91488 or saline. In addition, in stressed rats, the measurements were made before the immobilisation period. All the experiments were performed between 8.00. and 12.00 a. m.

Endogenous histamine concentrations were measured 15 min after SKF 91488 or saline treatment, since at that time the antinociceptive activities were most pronounced. After decapitation of rats, the brains were rapidly removed and the cerebral cortex, hypothalamus and medulla oblongata were quickly dissected on a glass plate chilled on ice, according to the procedure by Glowinski and Iversen (11). The samples were homogenised - the hypothalamus in 0.3 ml, the cerebral cortex and medulla oblongata in 10 volumes (w/v) of ice-cold 0.9% NaCl. After centrifugation, 100 µl of the supernatant was used for measurement of histamine concentration by commercially available enzyme immunoassay (Immunotech, France) without modifications. The sensitivity of the method was 0.2 nmol/l. The mean recovery of standard histamine was 92% (ranging from 87 to 111%).

The following drugs were used: SKF 91488, xylazine (Research Biochemicals Incorporated, USA), ketamine (Gedeon Richter, Hungary). All drug solutions were prepared fresh on the day of the experiment.

Fig. 1. Concentrations of histamine in the cerebral cortex, hypothalamus and medulla oblongata of the control (□) and SKF 91488-treated (▨) rats 15 min after *icv* injection; n=6; * p<0.05 and ** p<0.01 vs. the corresponding value in the control saline-treated group



All data are given as means ± S.E.M. with $p < 0.05$ considered as the level of significance. Differences between groups were analysed using a one-way analysis of variance. Significance of differences within groups over time was tested with a Student's t-test.

RESULTS

SKF 91488 produced an increase in endogenous histamine concentrations 15 min after treatment in the cerebral cortex (1.09 ± 0.11 vs. 0.61 ± 0.22 nmol/g; $p < 0.01$), hypothalamus (5.67 ± 0.64 vs. 4.11 ± 0.49 nmol/g; $p < 0.01$) and medulla oblongata (0.53 ± 0.19 vs. 0.32 ± 0.08 nmol/g; $p < 0.05$) in comparison to the saline-treated group (Fig. 1).

Table 1. Effects of SKF 91488 and restraint stress on the pain threshold in the rat paw pressure test (Randall-Selitto test); 6 to 9 animals per group; initial threshold pressure 63.6 ± 4.8 g; * $p < 0.05$ vs. the pre-treatment value; in the rats

Group	Pressure (g)				
	Time after <i>icv</i> treatment				
	15 min	30 min	45 min	60 min	120 min
Saline (5 µl <i>icv</i>)	62.4 ± 6.6	61.6 ± 5.1	64.5 ± 4.9	63.2 ± 3.3	64.3 ± 4.1
SKF 91488 (50 µg <i>icv</i>)	132.6 ± 6.8*	127.4 ± 7.4*	108.9 ± 7.6*	77.6 ± 5.8*	61.3 ± 3.9
SKF 91488 (100 µg <i>icv</i>)	159.3 ± 4.4*	141.5 ± 8.5*	123.1 ± 7.4*	92.4 ± 5.1*	64.8 ± 5.2
Restraint stress + saline (5 µl <i>icv</i>)	61.2 ± 4.9	63.2 ± 4.1	62.2 ± 3.1	61.4 ± 3.8	63.9 ± 4.2
Restraint stress + SKF 91488 (50 µg <i>icv</i>)	143.3 ± 5.9* #	138.6 ± 5.5* #	112.7 ± 6.1*	74.9 ± 6.2*	63.5 ± 4.7

Table 2. Effects of SKF 91488 and restraint stress on the pain threshold in the rat tail-flick test; 6 to 9 animals per group; initial time latency 5.3 ± 0.4 s; * $p < 0.05$ vs. the pre-treatment value; in the rats subjected for restraint stress # $p < 0.05$ vs. corresponding value in SKF 91488-treated group

Group	Tail-flick response (s)				
	Time after <i>icv</i> treatment				
	15 min	30 min	45 min	60 min	120 min
Saline (5 μ l <i>icv</i>)	4.9 \pm 0.7	5.3 \pm 0.6	5.4 \pm 0.5	5.3 \pm 0.6	5.2 \pm 0.4
SKF 91488 (50 μ g <i>icv</i>)	8.6 \pm 1.1*	9.7 \pm 1.4*	8.4 \pm 0.7*	7.7 \pm 0.8*	5.0 \pm 0.9
SKF 91488 (100 μ g <i>icv</i>)	15.0 \pm 0.0*	12.2 \pm 0.5*	9.9 \pm 1.7*	8.4 \pm 1.5*	4.8 \pm 1.5
Restraint stress + saline (5 μ l <i>icv</i>)	5.3 \pm 0.4	4.7 \pm 0.4	5.5 \pm 0.3	5.1 \pm 0.3	4.6 \pm 0.7
Restraint stress + SKF 91488 (50 μ g <i>icv</i>)	12.3 \pm 1.9* #	10.1 \pm 1.5*	8.6 \pm 0.6*	7.4 \pm 0.7*	5.3 \pm 0.8

There were no differences between the groups in initial nociceptive responses. The increase in endogenous central histamine concentrations, after inhibition of HNMT activity, was accompanied by a dose-dependent analgesic effect both in tail-flick test and Randall-Selitto test which were measured at 15, 30 and 45 min after treatment (Table 1, 2).

Restrain immobilisation stress did not influence histamine concentrations in comparison to non-stressed animals in the cerebral cortex (0.51 ± 0.11 vs. 0.60 ± 0.16 nmol/g), hypothalamus (4.37 ± 0.54 vs. 4.21 ± 0.59 nmol/g) and medulla oblongata (0.33 ± 0.14 vs. 0.28 ± 0.09 nmol/g). Moreover, it did not influence nociceptive responses (Table 1, 2). On the other hand, restraint stress potentiated SKF 91488-induced antinociceptive effect (Table 1, 2), however, without changes in central histamine concentrations 15 min after treatment in comparison to SKF 91488-treated group, the values being 1.13 ± 0.14 nmol/g in the cerebral cortex, 5.55 ± 0.79 nmol/g in the hypothalamus and 0.67 ± 0.29 nmol/g in the medulla oblongata.

DISCUSSION

The present study confirms the antinociceptive effect of endogenous histamine and the influence of the histaminergic system activation, resulting from restraint immobilisation stress, on the perception of pain. Thus the results are in agreement with the hypothesis that the central histaminergic system plays an important role in the activation of compensatory mechanisms, such as inhibition of pain transmission, in response to the action of adverse or potentially dangerous stimuli which disturb homeostasis.

The study confirms that SKF 91488 is an effective *in vivo* inhibitor of histamine N-methyltransferase and produces, after *icv* administration, an increase in central histamine concentrations. Similar effects of SKF 91488 on central histamine levels were demonstrated in the previous studies concerning the role of histamine in the central cardiovascular regulation (12, 13, 14).

The present results show that SKF 91488-induced increase in central endogenous histamine concentrations is associated with an antinociceptive effect measured in tests using two different kinds of noxious stimuli: thermal (tail-flick test) and mechanical (Randall-Selitto test). Similar results demonstrating antinociceptive action of endogenous histamine were obtained by Malm-

berg-Aiello at al. in the hot plate test and the abdominal constriction test in mice and the paw pressure in rats in the studies with three HNMT inhibitors metoprine, SKF 91488 and BW 301U (7, 8).

Studies of recent years concerning the physiological role of the histaminergic system suggest that it may be an important neuronal system involved in the recovery of disturbed homeostasis (1). Indeed, there is a general agreement that severe hypovolaemia, as a state of disturbed circulatory homeostasis, is accompanied by an activation of opioid and non-opioid (histaminergic, cholecystokoninergic, thyreoliberinergic) neuronal systems (15, 16, 17). Fundamental findings by Philippu et al. (18) demonstrate that the decrease in blood pressure after an intravenous injection of sodium nitroprusside or haemorrhage in cats is associated with the rise in the release of endogenous histamine from the posterior hypothalamus. Moreover, studies by Itoh et al. (19) show the increase in the brain level of a predominant metabolite of brain histamine tele-methylhistamine, however, without changes in histamine concentrations, resulting from different kinds of stress, including the exposure to tail pinch in rats and tail pinch, placing on a hot plate or subjecting to acetic acid-induced writhing in mice. Therefore, histamine turnover is altered under stress conditions, which leads to the mobilisation of the complex of compensatory mechanisms, including the increase in β -endorphin, ACTH and corticosterone secretion in stressed rats (1, 20). Earlier studies from our laboratory demonstrate that in critical haemorrhagic hypotension both exogenous histamine administered *icv* and endogenous histamine, after inhibition of HNMT activity, produce a dose-dependent long-lasting pressor effect accompanied by an increase in the survival rate (4, 14, 21, 22, 23). Interestingly, the pressor effects of histamine in rats subjected to critical haemorrhagic hypotension are two to three times higher compared to those in normotensive animals (4, 14), which demonstrates an important role of the histaminergic system in the maintenance of circulatory homeostasis in critical hypovolaemia.

The present study reveals, in tail-flick and Randall-Selitto tests, that restraint immobilisation stress, although it does not produce the increase in central histamine concentrations, influences pain transmission after SKF 91488 injection. The possible explanation of the effect is that restraint stress may produce a rise in endogenous histamine release, and may thus increase SKF 91488-induced endogenous histamine analgesic action. The results are in agreement with previous findings concerning the involvement of histamine in stress-induced antinociceptive action, since it has been shown that blockage of central histamine H_2 receptors inhibits footshock-induced antinociception in rats (24) and restraint-induced antinociception in female mice (25). Therefore, the present study supports the evidence on the role of the histaminergic system in the transmission of information from nociceptors in stress, which is of essential importance, especially in the critical stress.

In conclusion, the study confirms that SKF 91488 is an effective *in vivo* inhibitor of HNMT which increases central histamine concentrations and thus produces an antinociceptive action. Moreover, prior restraint immobilisation stress increases endogenous histamine-induced influence on pain transmission, which is in accordance with the hypothesis that the activation of the histaminergic system in situations of disturbed homeostasis mobilises compensatory mechanisms, including inhibition of information transmission from nociceptors, which is essential for escape and survival.

REFERENCES

1. Brown RE, Stevens DR, Haas HL. The physiology of brain histamine. *Progr Neurobiol* 2001; 63: 637-672.
2. Wada H, Inagaki N, Yamatodani A, Watanabe T. Is the histaminergic neuron system a regulatory center for whole-brain activity? *Trends Neurosci* 1991; 14: 415-418.
3. Schwartz J-C, Arrang J-M, Garbarg M, Pollard H, Ruat M. Histaminergic transmission in the mammalian brain. *Physiol Rev* 1991; 71: 1-51.
4. Jochem J. Cardiovascular effects of histamine administered intracerebroventricularly in critical haemorrhagic hypotension in rats. *J Physiol Pharmacol* 2000; 51: 229-239.
5. Jochem J, Pogorzelska T. Influence of histamine H_1 and H_2 and opioid receptor antagonists on antinociceptive reaction after histamine administered intracerebroventricularly in rats. *J Physiol Pharmacol* 1996; 47 (Supplement 2): 36.

6. Glick SD, Crane LA. Opiate-like and abstinence-like effects of intracerebral histamine administration in rats. *Nature* 1978; 273: 547-549.
7. Malmberg-Aiello P, Lamberti C, Ghelardini C, Giotti A, Bartolini A. Role of histamine in rodent antinociception. *Br J Pharmacol* 1994; 111: 1269-1279.
8. Malmberg-Aiello P, Lamberti C, Ipponi A, Hänninen J, Ghelardini C, Bartolini A. Effects of two histamine-N-methyltransferase inhibitors, SKF 91488 and BW 301U, in rodent antinociception. *Naunyn-Schmiedebergs Arch Pharmacol* 1997; 355: 354-360.
9. D'Amour FE, Smith DL. A method for determining loss of pain sensation. *J Pharmacol Exp Ther* 1941; 72: 74-79.
10. Randall LO, Selitto JJ. A method for measurement of analgesic activity of inflamed tissue. *Archiv Int Pharmacodynamic* 1957; 111: 409.
11. Glowinski J, Iversen LL. Regional studies of catecholamines in the rat brain. I. The disposition of [³H]norepinephrine, [³H]dopamine and [³H]dopa in various regions of the brain. *J Neurochem* 1966; 13: 655-669.
12. Klein MC, Gertner SB. Evidence for a role of endogenous histamine in central cardiovascular regulation: inhibition of histamine-N-methyltransferase by SKF 91488. *J Pharmacol Exp Ther* 1981; 216: 315-320.
13. Jochem J, Żwirska-Korczala K, Rybus-Kalinowska B, Jagodzińska J, Korzonek-Szlacheta I. Influence of SKF 91488, histamine N-methyltransferase inhibitor, on the central cardiovascular regulation during controlled, stepwise hemorrhagic hypotension in rats. *Pol J Pharmacol* 2002, in press.
14. Jochem J. Endogenous central histamine-induced reversal of critical haemorrhagic hypotension in rats – studies with histamine N-methyltransferase inhibitor SKF 91488. *Inflamm Res* 2002, in press.
15. Bertolini A. The opioid/anti-opioid balance in shock: a new target for therapy in resuscitation. *Resuscitation* 1995; 30: 29-42.
16. Little RA, Kirkman E, Ohnishi M. Opioids and the cardiovascular responses to haemorrhage and injury. *Intensive Care Med* 1998; 24: 405-414.
17. Jochem J, Joško J, Gwóźdź B. Endogenous opioid peptides in haemorrhagic shock – central cardiovascular regulation. *Med Sci Monit* 2001; 7: 545-549.
18. Philippu A, Hagen R, Hanesch U, Waldmann U. Changes in the arterial blood pressure increase the release of endogenous histamine in the hypothalamus of anaesthetized cats. *Naunyn-Schmiedebergs Arch Pharmacol* 1983; 323: 162-167.
19. Itoh Y, Oishi R, Nishibori M, Saeki K. Effects of nociceptive stimuli on brain histamine dynamics. *Jpn J Pharmacol* 1989; 49: 449-454.
20. Bugajski J, Gądek A. Central demonstrate H₁- and H₂-histaminergic stimulation of pituitary-adrenocortical response under stress in rats. *Neuroendocrinology* 1983; 36: 424-430.
21. Jochem J. Haematological, blood gas and acid-base effects of central histamine-induced reversal of critical haemorrhagic hypotension in rats. *J Physiol Pharmacol* 2001; 52: 447-458.
22. Jochem J. Central histamine-induced reversal of haemorrhagic shock versus volume resuscitation in rats. *Inflamm Res* 2002; 51 (Supplement 1): S57-S58.
23. Jochem J. Central histamine-induced reversal of critical haemorrhagic hypotension in rats – haemodynamic studies. *J Physiol Pharmacol* 2002; 53: 75-84.
24. Gogas KR, Hough LB. Inhibition of naloxone-resistant antinociception by centrally administered H₂-receptor antagonist. *J Pharmacol Exp Ther* 1989; 248: 262-267.
25. Wong C-L. Effects of a histamine H₂ receptor agonist and antagonist on restraint-induced antinociception in female mice. *Eur J Pharmacol* 1995; 279: 109-113.

Received: July, 4, 2002

Accepted: August, 15, 2002

SURFACTANT LUNG LAVAGE IN RABBITS WITH MECONIUM ASPIRATION – A PILOT STUDY

DANIELA ŠEVECŮVÁ¹, ANDREA ČALKOVSKÁ¹, ANNA DRGOVÁ², KAMIL JAVORKA¹

Department of Physiology¹ and Department of Medical Biochemistry², Comenius University,
Jessenius Faculty of Medicine, Martin, Slovakia

Abstract

Background and aim: Lung lavage with exogenous surfactant can improve an outcome of rabbits with meconium aspiration. We evaluated the effects of surfactant lavage on gas exchange, right-to-left pulmonary shunts, dynamic lung compliance and ventilatory parameters, as well as on the removal of meconium.

Methods: Adult rabbits were anesthetized, tracheotomized, paralyzed and connected to the ventilator (f. 30/min, Ti 60%). Suspension of human meconium was instilled into the tracheal cannula to induce respiratory failure. Subsequently, lung lavage was performed three times either with diluted surfactant (Surf group) or saline (Sal group). Animals were further conventionally ventilated (Ti 60%, PEEP 0.5 kPa) for additional one hour. Laboratory and lung function parameters were evaluated throughout the experiment.

Results: Administration of surfactant lavage significantly improved PaO₂/FiO₂ and oxygenation index ($p < 0.01$ and $p < 0.05$, respectively), decreased right-to-left pulmonary shunts 30 and 60 min after the lavage ($p < 0.05$) and slightly improved PaCO₂ and dynamic compliance, but both not significantly different to Sal group. Amelioration in outcome after the surfactant lavage was followed by the significant decrease in ventilatory pressures. Slightly higher amount of meconium was removed by surfactant lavage, however, in comparison to Sal group the difference was not significant.

Conclusion: We conclude that lavage with diluted surfactant improved an outcome and reduced requirements for ventilation in animals with meconium aspiration syndrome (MAS).

Key words: meconium aspiration, exogenous surfactant, lung lavage, rabbit

INTRODUCTION

Respiratory failure after meconium aspiration in neonates due to obstruction of the airways and ventilation-perfusion mismatch (1) is potentiated by inflammation (2) and inactivation of pulmonary surfactant (3, 4).

The inactivation of pulmonary surfactant by meconium and leaking plasma proteins can be to a high extent overcome by administration of exogenous surfactant. Applied exogenous surfactant replaces the functional losses of endogenous surfactant and increases the ratio surfactant:inhibitors (5). In addition, surfactant protects the lungs against edema and diminishes the inflammatory response. On the other hand, stabilization of the wall of alveoli and small airways by surfactant provides more homogenous distribution of ventilation followed by the reduction of right-to-left shunts, resulting in significant improvement in oxygenation (6), lung functions (7) and in better patient's outcome as well.

Nevertheless, application of the bolus of exogenous surfactant led in some patients to unexpected complications requiring administration of additional doses of the surfactant (8, 9). Experimental studies have demonstrated that administration of surfactant by lavage in acute lung injury can result in a better lung distribution and lower consumption of surfactant, because the material is uniformly distributed in the lungs (10, 11, 12). For this reason, administration of diluted surfactant by the lavage seems to be more suitable than the bolus application.

The clinical experience indicates that long lasting effects cannot be expected without the removal of significant portion of meconium from the airways. Meconium is extremely tenacious material with very low transportability (13). However, exogenous surfactant stimulates the mucociliary transport (14) and due to its surface properties surfactant works as an effective detergent that may facilitate the removal of meconium from the airways.

Address for correspondence:

Daniela Ševcová, MD, Department of Physiology, Comenius University, Jessenius Faculty of Medicine, Malá Hora 4, 037 54 Martin, Slovakia
Phone: ++421-43-4131426, fax: ++421-43-4222260,

Several recent studies have shown that lung lavage with diluted exogenous surfactant is able to improve oxygenation (15, 16, 17) and enhance the removal of meconium from the lungs (15, 16). Therefore, this study was mainly concentrated to the changes in right-to-left pulmonary shunts, dynamic lung-thorax compliance and requirements on ventilation after the surfactant lavage in adult rabbits with meconium aspiration, which have not been sufficiently elaborated yet.

METHODS

Meconium: Human meconium was collected from 30 healthy term neonates. The samples were pooled, lyophilized and stored at -20 °C. Before use, meconium was suspended in 0.9 % NaCl at a concentration of 25 mg/ml.

Surfactant: Porcine modified surfactant (Curosurf, Chiesi, Italy) was suspended in 0.9 % NaCl at a phospholipid concentration of 100 mg/kg, 10 mg/ml.

General design of the experiments:

Adult rabbits were anesthetized by an intramuscular administration of ketamine (Narkamon, Spofa, Czech Republic) at a dose of 20 mg/kg b.w. and xylazine (Rometar, Spofa, Czech Republic) at a dose of 5 mg/kg b.w. followed by continuous intravenous infusion of ketamine at a dose of 20 mg/kg/hour. A tracheotomy was performed and an endotracheal tube was inserted into the trachea. The femoral artery was cannulated for sampling arterial blood and monitoring blood pressure, the femoral vein for administration of drugs and anesthetics. The catheter in the right atrium, inserted through the jugular vein, was used for sampling mixed venous blood. To avoid spontaneous breathing, animals were paralyzed with pipecuronium bromide (Arduan, Gedeon Richter A.G., Hungary) at a dose of 0.3 mg/kg/30 min i.v. Animals were subjected to the pressure-controlled mechanical ventilator Beat-2 (Chirana, Slovakia) with the following ventilatory settings: frequency of 30 cycles/min, inspiration time (Ti) 60 %, fraction of inspired oxygen (FiO₂) of 0.21, tidal volume (V_T) of 8-10 ml/kg, positive end-expiratory pressure (PEEP)=0. After 15 min of stabilization, blood samples were taken for an analysis of partial pressures of O₂, CO₂ and pH by blood gas analyser (Radiometer, Denmark), hemoglobin by Specol 11 (Carl Zeiss, Germany) and ventilatory parameters: V_T, peak inspiratory pressure (PIP), PEEP were recorded. Tidal volume was measured by a heated Fleisch head connected to the pneumotachograph (UMMT SAV, Slovakia), airway pressure was registered via a pneumatic catheter placed in the trachea and connected to the electromanometer LDP 165 (Tesla, Czech Republic). Signals were transferred through the integrator unit to a multi-channel recorder 6 NEK 4 (RFT, Germany). Dynamic lung-thorax compliance was derived from the formula: $C_{dyn} = V_T / (PIP - PEEP)$, adjusted per kg b.w./ (PIP-PEEP), oxygenation index (OI) from: $OI = MAP \times FiO_2 / PaO_2$, where the mean airway pressure (MAP) was defined as $PIP + PEEP / 3$. Right-to-left pulmonary shunts (RLS) were calculated by a computer program by Fick equation, using measured values of partial pressures of O₂, CO₂ in the blood, FiO₂ and barometric pressure.

The model of meconium aspiration syndrome was described elsewhere (18). Briefly, a suspension of the human meconium in saline at a dose of 4 ml/kg b.w. was instilled into the tracheal cannula in the right and left lateral positions. FiO₂ was increased to 1.0, PEEP to 0.3 kPa and PIP was raised to maintain tidal volume of 8-10 ml/kg. After this, 4.2 % sodium bicarbonate (Braun, Germany) at a dose of 5 ml was administered to keep normal blood pH and furosemide (Furosemid, Hoechst-Biotika, Slovakia) at a dose of 5 mg/kg b.w. to promote diuresis. Within 30 min after the meconium administration, respiratory failure developed defined as > 30 % decrease in dynamic lung-thorax compliance (C_{dyn}) and $PaO_2 < 10$ kPa at FiO₂ 1.0. Blood sample analysis was done and lung function parameters were measured 30 min after the meconium administration.

Subsequently, PEEP was increased to 0.5 kPa and lung lavage was performed either with diluted surfactant (Curosurf, 100 mg phospholipids/kg, 10 mg/ml; Surf group) or normal saline (Sal group). Total dose of lavage solution (10 ml/kg) was divided into 3 portions. One third of the solution was instilled by the syringe into the tracheal cannula proportionally into the right and left lung during positioning and was suctioned after 1 and 5 min by the suction pump with negative pressure of 60 kPa. The whole procedure was repeated twice under the same conditions and volume of recovered liquid was determined. Animals were further ventilated (Ti 60%,

PEEP 0.5 kPa) for additional 1 hour. Blood samples were analyzed and lung function parameters were recorded 10, 30 and 60 min after the lavage. At the end of experiment, animals were killed by an overdose of anesthetics. Amount of meconium removed by the lavage was quantified by the spectrophotometric method according to Cochrane and co-workers (19).

Statistics: The statistical software package SYSTAT 6.0.1 For Windows (SPSS Inc., 1996) was used for data analysis. Data are expressed as median (interquartile range or IQR), because Kolmogorov-Smirnov one sample-test showed non-parametric distribution. Mann-Whitney U test for between-group comparisons and Wilcoxon signed ranks test for within-group comparisons were applied. A *p*-value < 0.05 was considered statistically significant.

Experiments were in concordance with basic ethical norms and Declaration of Helsinki.

RESULTS

Ten rabbits were used for data analysis, n=5 in each group. There were no significant differences between groups neither in gender rate nor in the body weight [2.3 kg (1.7-2.4) in Sal vs. 2.3 kg (1.6-2.5)] in Surf group .

Instillation of meconium seriously impaired the gas exchange and caused a respiratory failure with hypoxemia, acidosis and hypercarbia in both groups. Administration of surfactant lava-

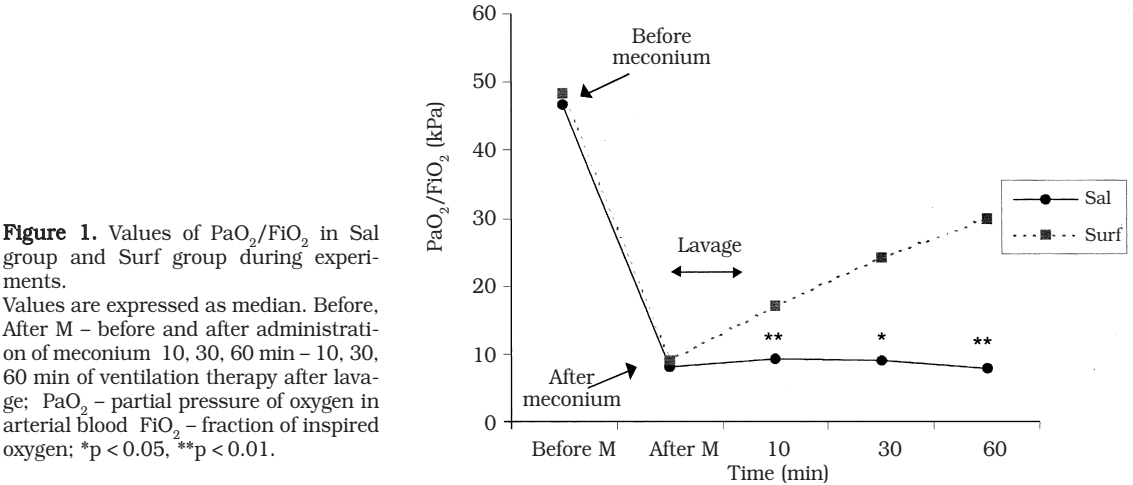


Table 1. Values of PaO₂/FiO₂, oxygenation index (OI), PaCO₂ and right-to-left pulmonary shunts (RLS) during experiments in animals with saline lavage (Sal group) and surfactant lavage (Surf group).

Parameters	Before M	After M	10 min Th	30 min Th	60 min
PaO ₂ /FiO ₂ -Sal (kPa)	46.8 (35.5-48.0)	8.1 (6.7-9.8)	9.2 (7.5-11.3)	8.9 (7.5-14.4)	7.9 (7.6-14.5)
PaO ₂ /FiO ₂ -Surf (kPa)	48.3 (39.7-57.9)	9.0 (6.8-9.7)	17.1 (12.8-21.6)**	24.2 (12.5-41.3)*	29.8 (17.7-34.6)**
OI-Sal	0.8 (0.6-1.0)	11.6 (8.2-13.5)	10.9 (9.7-14.7)	12.3 (7.0-14.6)	13.9 (6.9-15.4)
OI-Surf	0.8 (0.5-0.8)	11.7 (8.3-13.2)	5.3 (3.7-7.1)**	3.7 (2.2-8.0)*	2.9 (2.7-6.2)**
PaCO ₂ -Sal (kPa)	3.0 (2.5-3.8)	5.6 (3.1-7.1)	5.2 (4.4-8.7)	5.3 (3.5-7.9)	6.3 (3.4-7.0)
PaCO ₂ -Surf (kPa)	3.1 (2.7-3.9)	5.2 (3.8-7.2)	4.7 (3.1-6.3)	4.3 (2.9-5.4)	5.0 (3.6-5.7)
RLS-Sal (%)	9.8 (6.6-20.0)	37.5 (30.3-50.0)	40.0 (31.6-50.6)	40.6 (32.9-47.5)	46.6 (35.9-51.9)
RLS-Surf (%)	6.6 (5.9-11.4)	44.3 (33.9-53.0)	34.9 (33.2-44.8)	32.5 (21.9-37.2)*	28.3 (26.9-36.6)*

Values are expressed as median (interquartile range). Before, After M – before and after administration of meconium 10, 30, 60 min Th – minutes of ventilation therapy after lavage PaO₂, PaCO₂ – partial pressures of oxygen and carbon dioxide in arterial blood FiO₂ – fraction of inspired oxygen OI – oxygenation index RLS – right-to-left pulmonary shunts. **p* < 0.05, ***p* < 0.01 for between-group comparisons.

Table 2. Values of ventilatory parameters and dynamic lung-thorax compliance (C_{dyn}) during experiments in animals with saline lavage (Sal group) and surfactant lavage (Surf group).

Parameters	Before M	After M	10 min Th	30 min Th	60 min Th
V_T -Sal (ml/kg)	9.4 (8.0-9.8)	9.4 (8.4-9.8)	9.2 (8.9-9.8)	9.4 (8.4-9.9)	9.4 (8.4-10.0)
V_T -Surf (ml/kg)	8.8 (8.4-9.4)	9.4 (8.0-9.6)	8.8 (8.0-9.4)	9.4 (8.0-9.7)	9.2 (8.0-9.7)
PIP-Sal (kPa)	0.6 (0.5-0.9)	1.5 (1.3-1.7)	1.6 (1.4-1.8)	1.6 (1.4-1.8)	1.6 (1.4-1.9)
PIP-Surf (kPa)	0.7 (0.5-0.7)	1.4 (1.3-1.8)	1.4 (1.2-1.5)*	1.4 (1.3-1.5)*	1.4 (1.3-1.6)*
PEEP-Sal (kPa)	0	0.3 (0)	0.5 (0.4-0.5)	0.5 (0.4-0.5)	0.5 (0)
PEEP-Surf (kPa)	0	0.3 (0)	0.4 (0.3-0.5)	0.4 (0.4-0.5)	0.4 (0.3-0.5)
MAP-Sal (kPa)	0.3 (0.3-0.5)	0.9 (0.8-1.0)	1.1 (1.0-1.1)	1.1 (1.0-1.2)	1.1 (1.0-1.2)
MAP-Surf (kPa)	0.4 (0.3-0.4)	0.9 (0.8-1.1)	0.9 (0.8-1.0)**	0.9 (0.9-1.0)*	0.9 (0.8-1.1)*
C_{dyn} -Sal (ml/kg/kPa)	13.3 (10.4-19.6)	7.4 (6.7-9.8)	8.1 (6.7-10.9)	8.4 (6.7-11.0)	7.6 (6.7-10.9)
C_{dyn} -Surf (ml/kg/kPa)	12.6 (12.0-18.8)	7.5 (6.4-9.4)	8.8 (7.9-10.4)	9.4 (7.5-10.8)	9.2 (7.5-10.8)

Values are expressed as median (interquartile range). Before M, After M – before and after administration of meconium 10, 30, 60 min Th – minutes of ventilation therapy after lavage PIP – peak inspiratory pressure PEEP – positive end-expiratory pressure MAP – mean airway pressure C_{dyn} – dynamic lung-thorax compliance. * $p < 0.05$, ** $p < 0.01$ for between-group comparisons.

ge led to the significant improvement in oxygenation (expressed as PaO_2/FiO_2 in Fig.1 and Table 1, and OI in Table 1). After the surfactant lavage slightly increased CO_2 elimination was found, but without statistically significant difference between groups (Table 1).

Instillation of meconium caused the significant increase in right-to-left pulmonary shunts in both groups. Surfactant lavage reduced the shunting 30 and 60 min after the lavage procedure (Table 1).

The decrease in dynamic lung-thorax compliance (C_{dyn}) after the meconium administration was similar in both groups 44.4 % (35.6-54.7) in Sal group vs. 48.4% (39.2-50.3) in Surf group. C_{dyn} increased after surfactant lavage, however, the difference was not significant (Table 2).

Animals of both groups were ventilated with comparable V_T , PIP, PEEP and MAP before and after meconium administration. After the lavage procedure, ventilatory pressures were significantly lower in Surf group. Values of ventilatory parameters during the experiment in both groups are shown in Table 2.

Recovery of lavage fluid was similar in both groups [63.0% (52.1-79.6) in Sal group vs. 66.8% (53.8-83.8) in Surf group]. Percentual recovery of meconium evaluated spectrophotometrically showed slight increase in Surf group [13.0% (7.8-14.1) vs. 9.5% (9.3-12.1) in Sal group]. However, two samples from Sal group had to be excluded due to blood contamination of lavage fluid and thus the final number of samples was too small for data analysis.

DISCUSSION

Aspiration of meconium triggers a cascade of events leading to the deterioration of gas exchange and respiratory failure. Lung lavage with exogenous surfactant can partially alleviate inactivation of pulmonary surfactant and release the airway obstruction that may finally ameliorate an outcome.

Surfactant lung lavage in our study significantly improved oxygenation and showed the trend to increase elimination of CO_2 and lung compliance. Moreover, significant improvement was demonstrated also in right-to-left pulmonary shunts and ventilatory requirements. Slightly higher removal of meconium was found by the surfactant lavage, but the difference to saline group was not significant.

More homogenous distribution of ventilation after the surfactant lavage even to the parts of lungs that were previously collapsed behind the occlusion results in decreased ventilation-perfusion mismatch and finally in elevation of oxygenation. Better oxygenation found by recent studies (15, 16, 17) fully confirmed these postulates. Similarly, our study showed significant increase in oxygenation starting immediately after surfactant lavage and lasting for the rest of experiment.

Diminishing of ventilation-perfusion mismatch due to reduction of the airway obstruction leads to better CO_2 elimination. Significantly lower PaCO_2 after the surfactant lavage was shown in the previous studies (17, 20) and the present study also demonstrated decrease in PaCO_2 , but not significant to the saline group.

Percentage of right-to-left pulmonary shunts calculated by Fick equation is a valuable parameter describing the degree of ventilation-perfusion mismatch. This study demonstrated a significant drop in RLS 30 and 60 min after the surfactant lavage, probably related to a shifting of blood flow from poorly to better ventilated regions of the lungs. The study by Krause et al. (21) is only known, evaluating the right-to-left pulmonary shunts in MAS model, however, authors did not perform surfactant lung lavage.

Better aeration and reduction of the liquid and protein leak into the alveoli after the bolus of the surfactant may enhance the lung compliance, which was previously demonstrated by Sun and co-workers (6). Similar results were exhibited also by Ogawa et al. (22), who presented significant elevation in static lung compliance after the surfactant lavage and this effect was further potentiated by the bolus resupplementation after the surfactant lavage. We found improvement in dynamic lung-thorax compliance, however, the difference to the saline group was not significant.

Improvement in blood gases and lung function parameters showed above after the surfactant lavage caused that ventilatory pressures could be reduced. Sun et al. (7) also showed decreased requirements on ventilation in rats with meconium aspiration, however, the surfactant was administered in the bolus form, not as a lavage. Decreased ventilatory requirements minimize the negative adverse effects of artificial ventilation on diseased lungs. Especially in MAS the reduction of shear forces due to large pressure amplitudes is of high importance.

Recent experimental studies (15, 16, 19) showed improvement in histological and radiological appearance of the lungs after surfactant lavage in comparison to the saline lavaged or bolus surfactant-treated animals. Diluted surfactant effectively washed out meconium (20) and this effect might be dose-dependent (15). We performed the lavage with rather concentrated surfactant suspension, nevertheless, we were not able to exhibit obviously higher removal of meconium to the control group, probably due to small number of samples included for final data analysis. However, significant difference in removal of meconium between groups evaluated spectrophotometrically was not found either by Cochrane et al. (19) probably due to different lavage procedure and/or the evaluation method of meconium removal.

In conclusion, this study showed that surfactant lung lavage significantly improved oxygenation and right-to-left shunts and slightly increased CO_2 elimination and dynamic lung-thorax compliance. According to the improved outcome ventilatory pressures could be reduced. Our results, as well as the results of other experimental and pilot studies performed on neonates with MAS (22, 23) indicate that surfactant lavage can take part in the treatment of MAS.

Acknowledgement

We thank to Chiesi Farmaceutici SpA, Italy for supplying Curosurf and S. Svorková, D. Kulišková, I. Štritz and J. Benčatová for technical assistance. This study was supported by Grant VEGA No. 1/9288/02.

REFERENCES

1. Co E, Vidyasagar D. Meconium aspiration syndrome. *Compr Ther* 1990; 16 (10): 34-9
2. Davey AM, Becker JD, Davis JM. Meconium aspiration syndrome: Physiological and inflammatory changes in a newborn piglet model. *Pediatr Pulmonol* 1993; 16: 101-8
3. Moses D, Holm BA, Spitale P, Liu M, Enhorning G. Inhibition of pulmonary surfactant function by meconium. *Am J Obstet Gynecol* 1991; 164: 477-81

4. Oh MH, Bae CW. Inhibitory effect of meconium on pulmonary surfactant function tested in vitro using the stable microbubble test. *Eur J Pediatr* 2000; 159: 770-4
5. Sun B, Curstedt T, Robertson B. Surfactant inhibition in experimental meconium aspiration. *Acta Paediatr* 1993; 82: 182-9
6. Sun B, Herting E, Curstedt T, Robertson B. Exogenous surfactant improves lung compliance and oxygenation in adult rats with meconium aspiration. *J Appl Physiol* 1994; 77(4): 1961-71
7. Sun B, Curstedt T, Robertson B. Exogenous surfactant improves ventilation efficiency and alveolar expansion in rats with meconium aspiration. *Am J Respir Crit Care Med* 1996; 154: 764-70
8. Auten RL, Notter RH, Kendig JW, Davis JM, Shapiro DL. Surfactant treatment of full-term newborns with respiratory failure. *Pediatrics* 1991; 87: 101-7
9. Findlay RD, Taeusch HW, Walther FJ. Surfactant replacement therapy for meconium aspiration syndrome. *Pediatrics* 1996; 97: 48-52
10. Bleek J, Plötz FB, Overbeek FM, Beekhuis H, Wildevuur CRH, Okken A, Bambang Oetomo S. Distribution of exogenous surfactant in rabbits with severe respiratory failure: The effect of volume. *Pediatr Res* 1993; 34: 154-8
11. Balaraman V, Sood SL, Finn KC, Hashiro G, Uyehara CF, Easa D. Physiologic response and lung distribution of lavage versus bolus Exosurf in piglets with acute lung injury. *Am J Respir Crit Care Med* 1996; 153: 1838-43
12. Meister JC, Balaraman V, Ku T, DeSilva A, Sood S, Uyehara CF, Person DA, Easa D. Lavage administration of dilute recombinant surfactant in acute lung injury in piglets. *Pediatr Res* 2000; 47(2): 240-5
13. Rubin BK, Tomkiewicz RP, Patrinos ME, Easa D. The surface and transport properties of meconium and reconstituted meconium solutions. *Pediatr Res* 1996; 834-8
14. De Sanctis GT, Tomkiewicz RP, Rubin BK, Schürch S, King M. Exogenous surfactant enhances mucociliary clearance in the anaesthetized dog. *Eur Respir J* 1994; 7: 1616-21
15. Ohama Y, Ogawa Y. Treatment of meconium aspiration syndrome with surfactant lavage in an experimental rabbit model. *Pediatr Pulmonol* 1999; 28: 18-23
16. Lam BCC, Yeung CY, Fu KH, Wong KY, Chan FL, Tsoi NS. Surfactant tracheobronchial lavage for the management of a rabbit model of meconium aspiration syndrome. *Biol Neonate* 2000; 78: 129-38
17. Nakamura T, Matsuzawa S, Sugiura M, Tamura M. A randomised control study of partial liquid ventilation after airway lavage with exogenous surfactant in a meconium aspiration syndrome animal model. *Arch Dis Child Fetal Neonatal Ed* 2000; 82: F160-2
18. Ševcová D, Čalkovská A, Javorka M, Javorka K. Meconium aspiration syndrome – an experimental model. *Acta Med Mart* 2001; 1(1): 5- 8
19. Cochrane CG, Revak SD, Merritt TA, Schraufstatter IU, Hoch RC, Henderson C, Andersson S, Takamori H, Oades ZG. Bronchoalveolar lavage with KL₄-Surfactant in models of meconium aspiration syndrome. *Pediatr Res* 1998; 44: 705-15
20. Ohama Y, Itakura Y, Koyama N, Eguchi H, Ogawa Y. Effect of surfactant lavage in a rabbit model of meconium aspiration syndrome. *Acta Paediatr Jpn* 1994; 36: 236-8
21. Krause MF, Lienhart H-G, Haberstroh J, Hoehn T, Schulte-Mönting J, Leitis JU. Effect of inhaled nitric oxide on intrapulmonary right-to-left shunting in two rabbit models of saline lavage induced surfactant deficiency and meconium instillation. *Eur J Pediatr* 1998; 157: 410-5
22. Ogawa Y, Ohama Y, Itakura Y, Shimizu H, Kaneko K. Bronchial lavage with surfactant solution for the treatment of meconium aspiration syndrome. *J Jpn Med Soc Biol Interface* 1996; 26 (Suppl): 179-84
23. Lam BCC, Yeung CY. Surfactant lavage for meconium aspiration syndrome: A pilot study. *Pediatrics* 1999; 103: 1014-8

Received: July, 3, 2002

Accepted: July, 25, 2002

THE RESPIRATORY ADVERSE EFFECTS OF ENALAPRIL AND INHALED FUROSEMIDE

SOŇA FRAŇOVÁ, GABRIELA NOSÁLOVÁ

Department of Pharmacology, Comenius University, Jessenius Faculty of Medicine, Martin

Abstract

The chronic, dry cough is the most frequently occurring adverse effect of angiotensin converting enzyme (ACE) inhibitors therapy. The mechanism of this respiratory adverse effect is related to the inhibition of ACE and the accumulation of bradykinin, substance P, prostanoids and other inflammatory neuropeptides in the airways.

The aim of this study was to follow the relationship between 15-days enalapril administration and the sensitivity of the cough reflex in experimental animals and possibility of the pharmacological restriction with inhaled furosemide.

The sensitivity of the cough reflex was investigated by the method of the mechanical stimulation of the laryngopharyngeal and tracheobronchial area of the airways in conscious cats. The enalapril was administered for 15-days in the dosage of 5 mg/kg b.w. p.o., inhaled furosemide for 15-days in the dosage 10 mg/kg b.w.

The results suggested that long-lasting administration of enalapril resulted in a significant increase in number of efforts of mechanically induced cough. However, inhalation of furosemide in enalapril treated animals significantly decreased the enalapril induced cough.

The results showed the protective effect of inhaled furosemide against the respiratory adverse effects induced by ACE-inhibitors administration.

Key words: cough, enalapril, inhaled furosemide

INTRODUCTION

The inhibitors of angiotensin – converting enzyme (ACE) are the drugs of choice for the treatment of hypertension and congestive heart disease. However, it has been reported that in some patients ACE-inhibitors induce a dry, non-productive cough, with a frequency of occurrence between 0,2 – 37 %. Other airway reactions following ACE-inhibitor therapy, dyspnoe and wheezing, occur less frequently (1).

The therapeutic effectiveness of this pharmacological group is connected with the inhibition of enzyme angiotensin – convertase (kininase II), which plays a pivotal role in regulation of renin – angiotensin and kinin – kallikreine system. The mechanism of the respiratory adverse effects is unrelated to the inhibition of renin – angiotensin system, since treatment with angiotensin receptor blockers did not cause similar problems (2, 3). The negative effects of ACE -inhibitors on defence reflexes of the airways are linked with the metabolism of kinins and tachykinins and consequent accumulation of bradykinin (4), and substance P, neurokinin A and B in the respiratory tract (5). Additional factors, which enhanced the respiratory side effects of ACE –inhibitors, are the stimulation of phospholipase A₂ and the induction of mastocyte degranulation by bradykinine and substance P (6).

The above-mentioned pro-inflammatory mediators (bradykinin, substance-P, histamine, prostaglandins), whose level shows an increase in the airways after treatment with ACE-inhibitors, stimulate the rapidly adapting receptors myelinated vagal fibres (7) and unmyelinated C-fibres (8), and consequently provoke the cough reflex.

Clinical trials and experimental studies dealing with ACE – inhibitors treatment have been currently aimed at managing the cough induced by applying the above mentioned group of substances. According to our opinion, it is necessary to begin with a detailed knowledge of pathomechanism of the origin of the afore-mentioned adverse respiratory effects in order to select the substances capable to minimize or eliminate the side effects of the ACE-inhibitors in the respiratory tract. The basic condition that should be kept if the cough is to be eliminated by means of the pharmacological intervention consists in maintaining the primary pharmacological efficacy of ACE-inhibitors, thanks to which they are so widely used in clinical practice.

Address for correspondence:

RNDr. Soňa Fraňová, PhD., Department of Pharmacology JLF UK, Sklabinská 26
037 53 Martin, Slovakia
Phone : ++421 43 4132535, fax: ++ 421 43 4134807
e-mail: franova@jfm.uniba.sk

The aim of this study was to investigate the effect of the long-lasting administration of enalapril on the sensitivity of the cough reflex induced by the mechanical irritation of the laryngopharyngeal and tracheobronchial mucous membrane in the non-anaesthetized cats. The second phase of the study was to follow the possible effect of inhaled furosemide on the respiratory adverse effects of the enalapril.

METHODS

A method of the mechanical stimulation of the laryngopharyngeal and tracheobronchial area of the airways of non-anaesthetized cats of both sexes weighing 1500-2500 g was used in the experiment (9). After several days of quarantine, a tracheal cannula was surgically implanted into the animals, which served for the mechanical stimulation of the airways with nylon fibre 0.35 mm in diameter, as well as for recording the side tracheal pressure. The number of cough efforts /NE/, induced by repeated insertion (5 times) of the nylon fibre, was evaluated on the basis of the pressure values recorded during the experiment from both laryngopharyngeal (LPh) and tracheobronchial (TB) area of the airways. The values of the cough parameters measured before the application of the substances, represented the control values. During the experiment, enalapril and inhaled furosemide were applied 1 hour after induction of the cough. Enalapril was administered perorally as a saline solution in the dose 5 mg/kg b.w. to the first group of experimental animals ($n = 12$). The second group of animals ($n = 12$) was treated for 15 days with enalapril (dose 5 mg/kg b.w. perorally) and furosemide (dose 10 mg/kg b.w. by inhalation). Furosemide was administered by Pari Boy nebuliser with baby mask, approximately 15 minutes. The effect of enalapril and simultaneous administration of enalapril with furosemide on the cough parameters was monitored in the intervals 3, 5, 8, 10, 12, 15 days.

The results of this experiment were evaluated by Wilcoxon and Wilcoxon (10) method.

RESULTS

During 15-days enalapril administration (5 mg/kg/day) the sensitivity of the cough reflex was investigated by the method of a mechanical stimulation of the airways in non-anaesthetized cats. Based on the results, in 3, 5, 8, 10, 12, 15 day of enalapril administration it was found that a statistically significant increase of the number of cough efforts (NE) occurred from laryngopharyngeal and tracheobronchial mucous membrane of the airways (Fig. 1).

Simultaneous 15-days applications of the enalapril with inhaled furosemide (10 mg/kg/day),

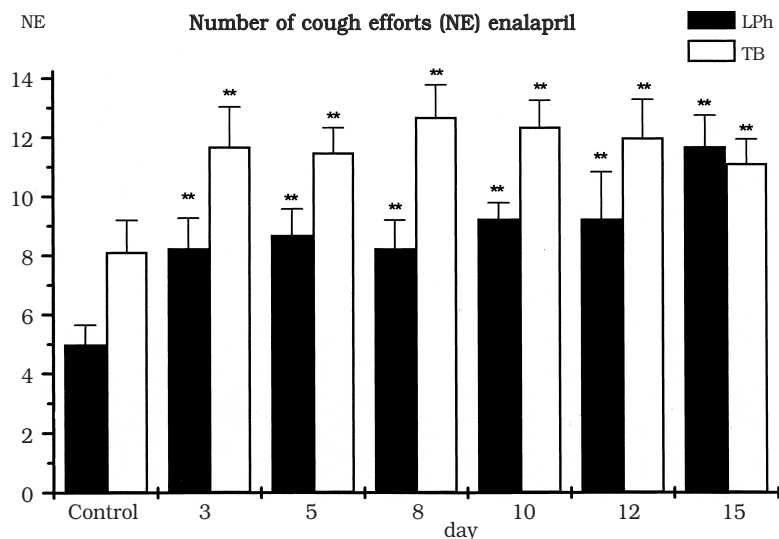


Fig. 1. Changes in the number of cough efforts (NE) from laryngopharyngeal (LPh) and tracheobronchial (TB) area of the airways of the non-anaesthetized cats before enalapril administration (Control) and during 15-days enalapril administration. The columns represent average values, the dispersion is mean error of average. Statistical significance was calculated according to Wilcoxon - Wilcoxon test (* $p < 0.05$, ** $p < 0.01$).

Fig. 2. Changes in the number of cough efforts (NE) from laryngopharyngeal (LPh) and tracheobronchial (TB) area of the airways before drug administration (Control) and during 15-days administration of enalapril + inhaled furosemide.

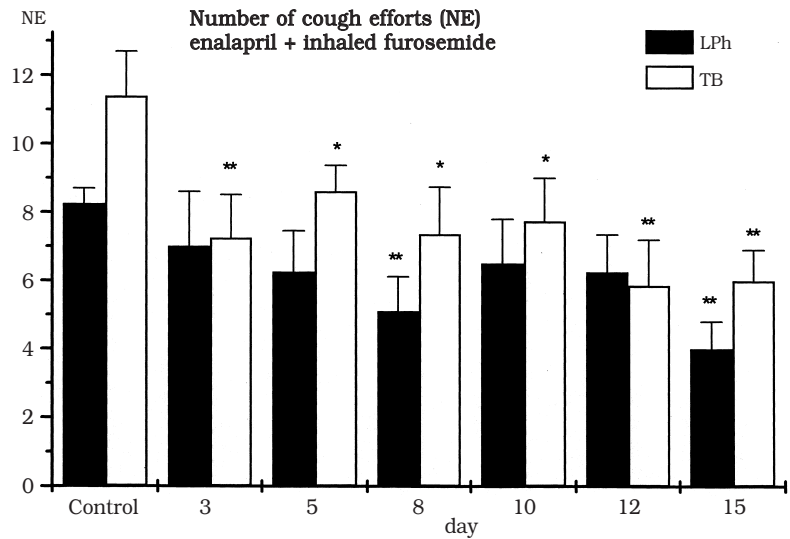
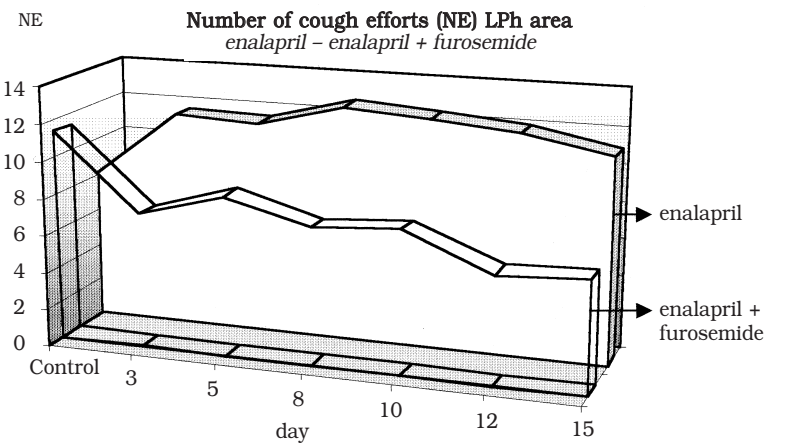
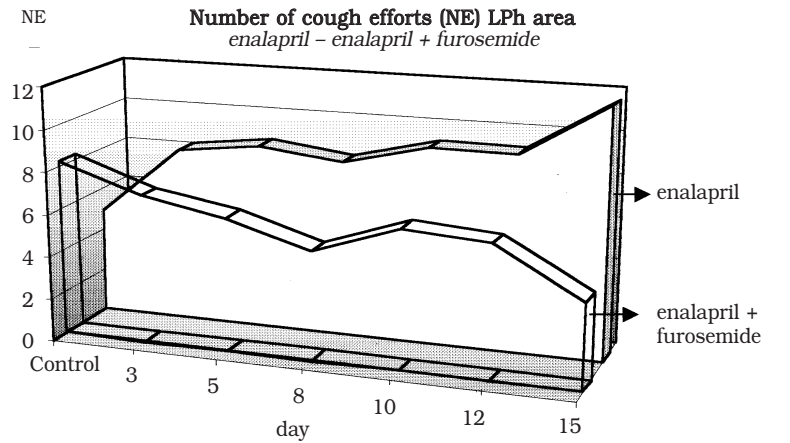


Fig. 3. The comparison of the number of cough efforts from laryngopharyngeal (LPh) and tracheobronchial (TB) area of the airways before drug administration (Control), after 15-days enalapril administration and after 15-days administration of enalapril with inhaled furosemide.



in comparison to enalapril monotherapy resulted in the significant decrease of the number of the cough from the laryngopharyngeal and tracheobronchial area of the airways (Fig.2).

Fig 3. compares the changes in the number of cough efforts from laryngopharyngeal and tracheobronchial region of the airways, during 15-days enalapril monotherapy, and during combined therapy enalapril with inhaled furosemide.

DISCUSSION

In our experimental conditions, the 15 days application of enalapril in the dose of 5 mg/kg/day induced statistically significant increase in the parameters of a mechanically provoked cough from laryngopharyngeal and tracheobronchial area of the airways. This negative influence on the respiratory tract, evoked by enalapril administration, was suppressed after the application of enalapril with inhaled furosemide.

Taking into consideration the basic goal of applied ACE-inhibitors and in order to struggle for elimination of their adverse effect to the respiratory system, our attention has been aimed at the inhaled furosemide. Furosemide is a loop diuretic which alters ionic flux in other epithelial cells and in other neuronal tissue by inhibiting the $\text{Na}^+2\text{Cl}^-\text{K}^+$ co-transport (11). Furosemide has a beneficial effect on modulation of the defence reflexes of the airways, and one of them has the inhibitory effect on the cough response induced by the wide range of the stimuli. In experimental conditions, furosemide inhibited the cough induced by inhalation of low-chloride-content solutions in guinea pigs (12). It has been suggested that furosemide may be acting indirectly, perhaps by changing the concentration of Cl^- ions in periciliary liquid and in this way is capable to alter the sensitivity of the cough receptors – RARs (rapidly adapting receptors) of the myelinated fibres and the endings of the unmyelinated C-fibres (13). In addition, furosemide inhibits the cholinergic and noncholinergic-nonadrenergic transmission in the airways. Inhalation of furosemide has been shown to be effective in preventing bronchoconstriction induced by several stimuli such as exercise, allergens, bradykinin (14), cold air, metabisulphite, adenosine (15, 16), leukotriene LTD_4 (17). Bronchodilatory effect of furosemide could participate in the cough suppressing activity of this substance.

In our experiments, focused on the comparison of the number of cough efforts during 15-day enalapril monotherapy and during 15 day inhalation of furosemide in enalapril treated animals, we observed the significant decrease of the parameters of a mechanically induced cough after combined therapy of enalapril with furosemide. This finding showed that inhaled furosemide is able to suppress the enalapril induced cough. Because the mechanical irritation of the airways is a relatively selective stimulus for the induction of cough by the rapidly adapting receptors (18), our results confirmed the participation of RARs either in the production of the cough after enalapril treatment or in the suppression of the cough reflex after furosemide inhalation.

In conclusion, our experimental data provide consistent evidence of negative respiratory effects of ACE-inhibitors accompanied with increased incidence of mechanically induced cough. Simultaneous application of inhaled furosemide with perorally administered enalapril showed that furosemide unambiguously succeeded in the restriction of the respiratory adverse effects of ACE-inhibitors.

REFERENCES

1. Israili ZH, Hall, D. Cough and angioneurotic edema associated with angiotensin-converting enzyme inhibitor therapy. *Ann Intern Med* 1992; 117: 234 – 242.
2. Goldberg MR, Mey CH, Wroblewski JM, Li G, Schroeter V, Belz GG. Differential effects of oral losartan and enalapril on local venous and systemic pressor responses to angiotensin I and II in healthy men. *Clin Pharmacol Ther* 1996; 1: 72 – 82.
3. Benz, J, Oshrain C, Henry D, Avery C, Chiang YT, Gatlin M. Valsartan, a new angiotensin II receptor antagonist: a double blind study comparing the incidence of cough with lisinopril and hydrochlorothiazide. *J Clin Pharmacol* 1997; 37 (2): 101 – 107.
4. Fox AJ, Lalloo UG, Belvisi, MG, Bernareggi M, Chung KF, Barnes PJ. Bradykinin evoked sensitisation of airway sensory nerves: a mechanism for ACE-inhibitor cough. *Nature Med* 1996; 2: 814 – 817.

5. Sekizawa K, Jia YX, Ebihara T, Hirose Y, Hirayama Y, Sasaki H. Role of substance P in cough. *Pulm Pharmacol* 1996; 9: 323 – 328.
6. Trifilieff A, Da Silva A, Gies JP. Kinins and respiratory tract diseases. *Eur Respir J* 1993; 6: 576 – 587.
7. Hargreaves M, Ravi K, Senaratne MPJ, Kappagoda CT. Responses of airway rapidly adapting receptors to bradykinin before and after administration of enalapril in rabbits. *Clin Sci* 1992; 83: 399 – 407.
8. Fox AJ. Modulation of cough and airway sensory fibres. *Pulm Pharmacol* 1996; 9: 335 – 342.
9. Nosáľová G, Strapková A, Kardošová A, Capek P. Antitussive activity of a rhamnogalacturonan isolated from the roots of *Althaea officinalis* L., var. *Robusta*. *J. Carbohydrate Chemistry* 1993; 12: 589 – 596.
10. Wilcoxon F, Wilcox RA. Some rapid approximate statistical procedures. New York: Lederle Laboratory Division of American Cyanamid Co. Pearl River; 1964, p. 60.
11. Bianco S, Pieroni MG, Refini RM, Robushi M, Vaghi A, Sestini P. Inhaled loop diuretic as potential new anti-asthmatic drugs. *Eur Respir J* 1993; 6: 130 – 134.
12. Fox A, Barnes PJ, Dray A. Stimulation of guinea pig tracheal afferent fibres by non-isoosmotic and low chloride stimuli and the effect of frusemide. *J Physiol* 1995; 482: 179 – 198.
13. Korpáš J, Nosáľová G. *Farmakoterapia kašľa*. Martin: Osveta; 1991, s. 336.
14. Polosa R, Rajakulasingan K, Prosperini G, Magri S, Mastruzzo C, Holgate ST. Inhaled loop diuretics and basal airway responsiveness in man : evidence of a role for cyclo-oxygenase products. *Eur Resp J* 1995; 8: 593 – 599.
15. Vaghi A, Robuschi M, Sestini. Comparison of inhaled frusemide and bumetamide in preventive ultrasonically nebulized water bronchoconstriction. *Eur Respir J* 1990; 3: 93 – 95.
16. Barnes PJ. Diuretics and asthma. *Thorax* 1993; 48: 195 – 196.
17. Cheung D, Bel EH, Van der Veen H, Dijkaman JH, Sterk PJ. The effect of inhaled frusemide on histamine and leukotriens – induced airway narrowing in asthmatic subjects. *Eur Resp J* 1990; 4: 605.
18. Nosáľová G: Mechanism of action of the drugs influencing the cough reflex. *Bratisl Lek Listy*, 1998; 99(10): 531 – 535.

Received: January, 9, 2002

Accepted: April, 15, 2002

DERMATOLOGIC TUMORS FINDINGS IN A JUVENILE HYALINE FIBROMATOSIS ADULT PATIENT DURING 7-YEAR- FOLLOW-UP

KATARÍNA ADAMICOVÁ², ŽELMÍRA FETISOVOVÁ¹, JURAJ PEČ¹, DAGMAR STATELOVÁ³,
YVETTA MELLOVÁ⁴, HUBERT POLÁČEK⁵, NAĎA MIŠOVICOVÁ⁶

¹Department of Dermatovenereology, Jessenius Faculty of Medicine, Comenius University in Martin (JLF UK)

²Department of Pathological Anatomy JLF UK

³Department of Stomatology JLF UK

⁴Department of Anatomy JLF UK

⁵Department of Radiodiagnostics, Martin Faculty Hospital

⁶Department of Clinical Genetics, Martin Faculty Hospital
Slovak Republic

Abstract

Background: Juvenile hyaline fibromatosis (JHF) is a rare autosomal-recessive hereditary disease. The typical clinical features are nodules and tumors growing in the skin and soft tissues as well as hypertrophic gingiva. Most of JHF patients have stunted growth, suffer from joint disorders, contractures, osteolytic lesions and have positive family history. This disease is frequent in children but it may be diagnosed in adult age. Only several cases of this disease have been presented in the literature since Murray (13) described its first case.

Purpose: Complete description of clinical as well as histologic, immunohistologic and electron microscopic picture of JHF in adult patient followed up for 7 years, presentation of not yet described skin lesions diagnosed in this JHF patient: mixed panniculitis, clear-cell acanthoma, skin papillomas and fibromas, papillomatosis of the upper lip and rhinophyma.

Results: Clinical, histopathological and electron -microscopic descriptions of JHF case diagnosed in adult age and followed up for 7 years are in agreement with published data.

Immunohistochemically the tumor cells showed positive immunoreactions for vimentin, alpha-1-antitrypsin, alpha-1-antichymotrypsin and CD 68. There were negative reactions for lysozyme, actin, desmin and S-100 protein. The proliferative marker PCNA was positive in minimum tumor cells (in less than 1 %).

Conclusions: We describe a very rare disease of children found in an adult man who has been followed-up for 7 years. Dermatoses not previously described in JHF patients are presented. An interdisciplinary approach in treatment of this patient improved his quality of life.

Key words: juvenile hyaline fibromatosis, clinical picture, histopathology, immunohistochemistry, the quality of life.

CASE REPORT

Two months after his birth, the patient developed contractures and he could not raise his hands and stretch his legs. At the age of 2 he was hospitalized for arthrogryphosis and pronounced hyperplasia of the epithelium around his wings of nose, behind his auricles, gingival hypertrophy and perianal fibromas.

One year later, the patient was again hospitalized for plastic surgery of his gingiva. At the age of 4 he was admitted to hospital with impetigo and retroauricular dermatitis. In this period due to contractures of the large joints he was unable to stand or walk. He had plum-size tumors on his head and chest. There was no sign of his mental retardation.

His parents are healthy, allegedly non-consanguineous persons, but their families come from the same small village. The patient had one somatically normal sister who died of leukemia at the age of 13. Two of his cousins were disabled, unable to walk and speak, they died at the age of 14 (male) and 20 (female).

PHYSICAL EXAMINATION AND SKIN FINDINGS

A 28-year-old male patient, 147 cm tall, weighing 31 kg (examined for the first time at the Department of Dermatovenereology, JLF UK, Martin Faculty Hospital, in July 1994), was admit-

Address for correspondence:

Ass. Prof. K. Adamicová, MD, PhD, Dept. of Pathol. Anatomy, JLF UK, Kollárova 2, 036 01 Martin

e-mail: adamicova@jfmf.uniba.sk

ted to the hospital for signs of secondary impetigo on large areas of his trunk, abdomen and for pachyderma on his limbs. Polymalformation syndrome with dominating signs of stunted growth, severe arthrogryphosis with immobility, pronounced skeletal deformations, subcutaneous painless tumors on the forehead, auricles, trunk (Fig. 1), knees and elbows, were noted. Only the tumors in the places exposed to pressure were painful. The size of the lesions was from 2 x 2 to 10 x 5 cm. The tumors were firmly elastic, and in the occipital region they were hairless. There were gross gingival enlargement with defective dentition, a large head, very fat complexion and rhinophyma. There were papillomatous foldson the upper lip; the trunk was deformed; severe scoliosis with osteoporosis of vertebrae was present; upper extremities were thin, with muscular atrophy; and there were contractures in the arm, elbow and wrist joints. The fingers were deformed and thickened, with flexural contractures. There were contractures on the lower extremities; the upper leg were impressively thin, with pachyderma and pronounced lymphoedema of the lower leg and feet. The nails were thickened and long. Size of male genital corresponded with the patient's age and there was lymphoedema of the scrotum. Smaller papillomatous tumors were present in the genitofemoral and perianal regions. During hospitalization the patient was febrile, and developed painful, firm deposits on the anterior side of the thigh and in the region of the knee. Mixed septal-lobular panniculitis was histologically confirmed.

One year prior to his first admission he was on macrobiotic and vegetarian diet. Even though he never attended school, he was able to read, his handwriting was very neat, and answers to questions were sensible.

During his following six hospitalizations, growth of typical JHF nodules and tumors was observed. In surgical removal of cutaneous and subcutaneous tissues, clear-cell acanthoma, minor skin fibromas and papillomatosis of the upper lip were histologically proven.

EXAMINATIONS

From the complex laboratory and other clinical examinations we are presenting the following ones: mild-degree anaemia with mild hypochromia, sideropenia and hypocalcemia which were changed to normal during the first hospitalization. Increased inflammatory activity (FW, ASLO, CRP, Muko, hypergamaglobulinemia), during the first hospitalization, was put to normal level. Hepatic tests were normal. Sonographic examinations of the abdominal organs, thyroid gland and parathyroid glands, lungs and heart did not show any pathological changes. Skin smear: *Staphylococcus aureus* and *Streptococcus pyogenes* were found during the first hospitalization. Analysis of the amino acids in the urine showed non-specific hyperaminoaciduria, serum glycine increased to the upper limit. Levels of organic acids and oligosaccharides were normal. Mukopolysaccharides and creatine levels in urine reached the upper limits. Results of the urine and blood examinations made in the Department of Hereditary Metabolic Disorders, VFN and 1st LFUK in Prague did not confirm any disorder in urate metabolism. Normal male caryotype 46,XY was confirmed in the cytogenetic examination.

Radiographic examination: Numerous tumors with large calcifications and pronounced skeletal changes (Fig. 2) as well as osteolytic deposits were observed. Scintigraphy of the whole body showed centers of increased osteoblastic activities in the regions of big joints and active deposits of ectopic ossification in the regions of head, trunk and neck.

Brain CT showed small ischemic deposit in the right periventricular aspect, mild brain atrophy and in the right peritemporal and occipital aspects extracranial tumor masses in the soft tissues. Ear examination showed otitis media chronica epitympanica. Eye examination showed hypermetropia.

During the patient's hospitalization his painful and interfering tumors, papilomatous growths and skin nodules were surgically removed, his teeth were repaired, skin impetiginization and panniculitis were properly treated generally or locally. The quality of life of the patient was improved with diet containing meat and milk, through intensive nursing care providing psychic comfort, through at least partial improvement of self-care as well as through instructing his parents how to take care of his skin.

HISTOLOGIC FINDINGS

Histopathologic findings in numerous specimens from the skin tumors examined during all the patient's hospitalizations were similar. The epidermis was normal except from non-specific inflammatory changes in it. Deep in the dermis, there were observed tumor masses which morphologically showed potential growth and they were infiltrated with collagen. Tumor cells were embedded in a homogenous eosinophilic substance with well-delimited fibrous elements in deposits. Tumor cells, whose number was different in single excisions, had oval-shaped nuclei containing finely dispersed chromatin. In some cells the nucleolus was quite well-delimited. Multi-nuclear elements were also observed. The cytoplasm was quite abundant, slightly eosinophilic and granular. Cytoplasmic membrane in some cells was clearly recognized, in others not. There were numerous cells in the artificial peripheral halo. The ratio of the cell elements in the ground substance varied among the single tumor excisions, and even within one tumor. Some parts of the lesion were rich in cellular deposits, others in ground substance. In general, the older tumors contained more ground substance. In the younger and newly developed tumors, numerous cells were embedded in their periphery, while the cell populations in the centers were poor.

Other histologic characteristics included the finding of the amorphous or even osteoid substances in the margins as well as in the centers of deposits. Dilated blood vessels and non-specific, mostly chronic, inflammatory infiltrate of various intensity, with neutrophil detritus in painful lesions, were also observed. Similar findings were obtained from the gingival tumor lesions, but also with much more severe inflammation present, with a few „cementicles“ and osteoid formation in the ground substance.

Special Histologic Methods

The amorphous ground substance was distinctly PAS-positive and resistant to amylase digestion. Alcian blue staining with pH 2.5 and 5.8 of different critical concentration was negative. Metachromasia was occasionally observed in deposits with toluidine blue. Amyloid was negative with Congo red and thioflavine T. Van Gieson stained pale orange and Giemsa stained pale pink. Silver impregnation showed irregular, somewhere absent intertwining reticulum fibres. Elastic fibres in Lawson method were absent or were very disorganized. Hemosiderin in Pearlson's method was absent. With Kossa's impregnation positive reaction particularly in the gingival excisions and rarely also in the skin excisions were seen.

Immunohistochemical Examination

Material in formalin and paraffin was processed against a panel of monoclonal and polyclonal antibodies using positive and negative controls. The tumor cell showed positive immunoreactions for vimentin (VIM) (Fig. 3), alpha-1-antitrypsin (AAT) and alpha-1-antichymotrypsin (AACT) and CD 68 (Fig. 4). There were negative reactions for lysozyme, actin, desmin and S-100 protein. The proliferative marker PCNA was positive in minimum tumor cells (in less than 1 %).

Marker p53 was negative. In the dilated capillaries the F-VIII positivity in endothelial cells was normal. EMA and polyclonal cytokeratines were not detected. Laminin and collagen IV of the basal membrane antigens were not present in the hyaline matrix. All antigens used, except for S-100 protein (Biogenex), were produced by the firm DAKO.

Electron Microscopy

Tissue was fixed by immersion in 2 % glutaraldehyde in 0.1 M phosphate buffer at pH 7.2. After washing in buffer, the tissue was postfixed in Buffered 0.1% OsO₄ solution at pH 7.2. After dehydration in alcohols, the tissue was embedded in Durcupan (ACM-Fluka). The ultrathin sections were stained with uranyl acetate and lead citrate.

Elongated fibroblast-like cells were found in the examined lesions. Most nuclei were oval-shaped, with prominent nucleolus and deep nuclear membrane/envelope folds. The nuclear membrane was marked by condensed chromatin. The cytoplasm showed dilated rough endoplasmic reticulum cisterns and enlarged sacs of Golgi complexes containing amorphous material (Fig. 5).

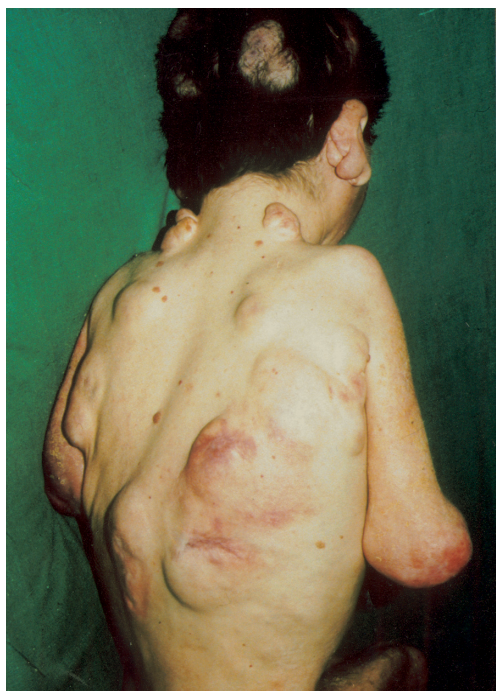

Fig. 1 Patient with tumorous skin lesions on the head, auricles, neck and trunk.

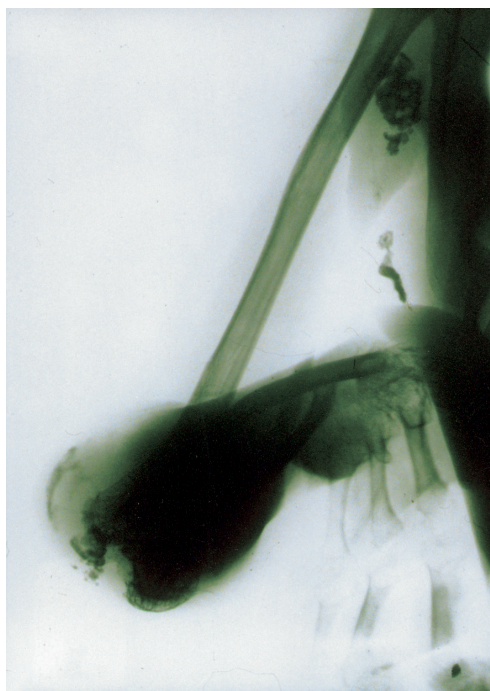

Fig. 2 Dystrophic ossification in JHF. Right arm – RTG picture.

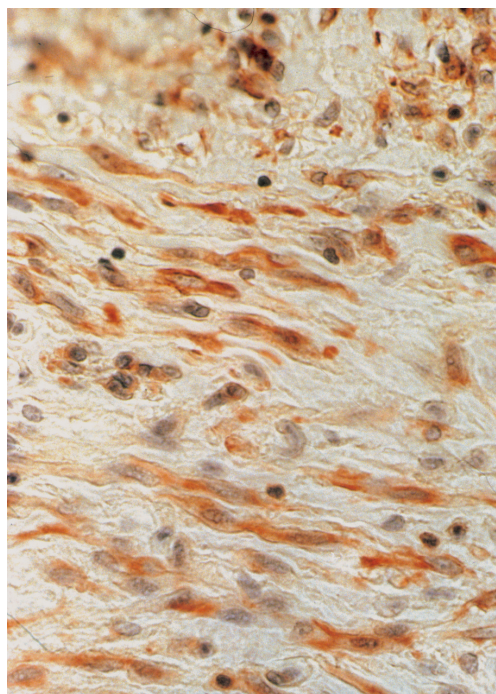


Fig. 3 Elongated cells in JHF tumor lesion with positive anti vimentin in the cytoplasm (DAKO). Vimentin, 280 x.

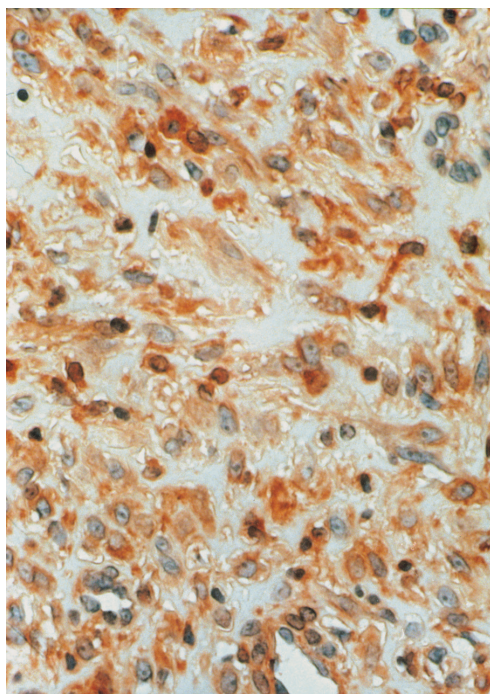


Fig. 4 Round-shaped cells in JHF tumor lesion with positive alpha-1-chymotrypsin, alpha-1-antichymotrypsin and CD 68 in the cytoplasm. CD 68, 280 x.

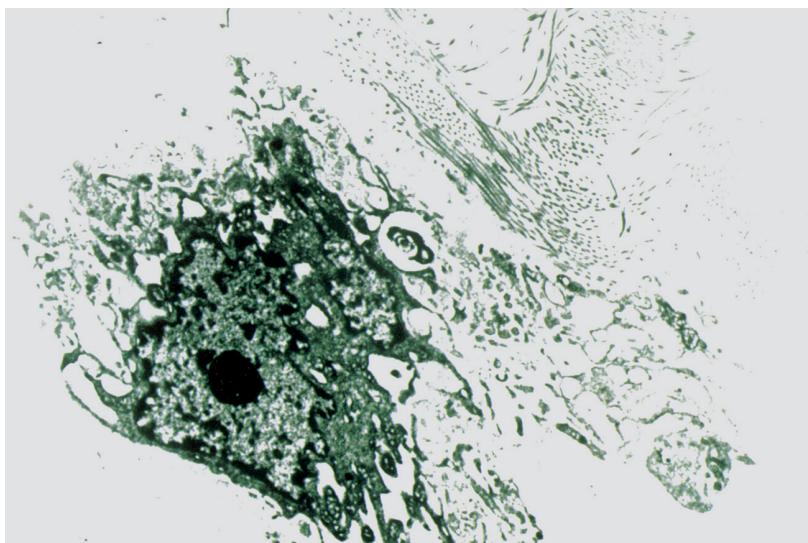


Fig. 5 Fibroblast – like cells. The cytoplasm showed dilated rough endoplasmatic reticulum cisterns and enlarged sacs of Golgi complexes containing amorphous material. EL MI, 6 000 x.

The cells were embedded in the ground substance. Clusters of collagen fibers went in various directions. Concentric formations of density similar to calcium were found in the cytoplasm.

DISCUSSION

JHF is a disease of connective tissue first described by Murray in 1873. It is also referred to as puretic syndrome, system hyalinosis, disseminated painful fibromatosis, hyaline numerous juvenile fibromatosis (1), mesenchymal dysplasia (14). At present there are about 40 cases of this disease reported in literature (20) and the term of juvenile hyaline fibromatosis is preferred (6,9,12).

JHF is a disease of younger children. The skin signs start to appear usually between the 2nd and 5th year of age (14). However, it can be diagnosed also in adult age (20, 3), which is confirmed by our case. McKee (12) presents the cases of spontaneous regression of subcutaneous tumors that cannot be confirmed by our case history and clinical observations. On the contrary, during 7 years of our patient's follow-up, we observed the occurrence of new nodules and tumors.

This disease is ranked among hereditary diseases (4), which was confirmed also in the case history of our patient.

The onset of this disease in our patient is recorded in his case history when he was two months old (contractures of limbs). At the age of four arthrogryphosis and hyperplasia around his alae nasi, around postauricular folds and gingival hyperplasia were diagnosed. In spite of the fact that we have no data from his previous histopathologic diagnosis, we suppose that they were the first characteristic JHF changes, as stated also in literature (13). Tumors in our patient were present on his forehead, auricles, scalp, knees, fingers and on his lower leg, i.e. typical locations stated in literature.

The tumor lesions on the patient's neck and back were painful which corresponds with their descriptions by several authors (17). Because other lesions were never reported as painful, we think that it is a secondary pain resulting from the pressure on the tumor's tissue. According to our patient's information his tumors were inveterated and caused scarring. During our 7-year-follow-up we did not observe such course of changes. Multiple osteolytic defects (5) reported in radiological examinations were found in our patients especially in long bones and phalanges.

Hypochromic anemia and hyperproteinemia were reported in JHF by Puretic et al. (15) and Aldred and Crawford (1), were found also in our patient. Neither hypoglycaemia nor long-lasting diarrhea were present.

Repeated infections are reported in patients with JHF. Impetigo and otitis media with fevers before our patient's first hospitalization were treated by his family physician with antibiotics. Large skin impetiginization was probably due to poor hygiene resulting from limited mobility of the patient. Examination of the renal secretion of calcium and phosphorus excluded hypercalcuria as the cause of hypokalcemia, secondary hyperparathyreosis in renal failure, as well as conditions with lower secretion (no effect) of parathyrin as the cause of ectopic calcifications. JHF is not included among genetic disorders manifested in soft tissue calcifications (11). Histological findings excluded acquired forms of general, localised ectopic calcifications as well as neoplastic heterotopic ossification processes in the soft tissues (16). According to these findings, our patient probably had dystrophic localised calcification (12). JHF is sometimes reported to be accompanied by mental retardation (12). Our patient was found to be mentally subnormal but this condition was ascribed to his social surroundings. This is in agreement with reported normal mental development in JHF patients which is considered to be a differential diagnostic sign in relation to mucopolysaccharidosis (7).

Diagnosis of this case was made in bioptic examination of the tumorous lesions in the subcutis and gingiva. The figure we present corresponds with the descriptions of lesions from several authors (9).

Negative alcian blue staining found by means of special methods we used contradicts the slight positivity in matrix tumor lesions found by Chitala et al. (8) and the positive finding of Remberger et al. (18). We think that the varied presence of acidic mucopolysaccharides in the lesions depends on their location and age.

We did not find any results of immunohistochemical examinations of JHF tumor cells in the literature. Remberger et al. (18) examined basal membrane for the presence of antigens. They did not find positive laminin and collagen IV structures in the hyaline matrix which is in agreement with our findings. Because of exprimation of vimentine by the cells of tumorous lesion they are elements of mesenchymal origin. Presence of alpha-1-trypsin, alpha-1-antichymotrypsin and CD 68, in the cytoplasm is not very important for differential diagnosis of the tumors in soft tissues because they are detectable in various cell of tumor or non-tumor origin and are considered as markers of monocyte-histocyte system (MHS) (19). Presence of AAT and AACT therefore points to a possible MHS origin of the examined tumor cells. Proliferative activity (PCNA) is minimum. It can be observed only in the cells excised from younger nodules. Our electron-microscopic picture is in agreement with other data in the literature (2).

The other findings on the skin that we observed and diagnosed during 7-year- follow-up study have not been described so far in the works on JHF we know.

We consider papillomatosis of the upper lip as well as papilomatous and fibromatous changes in perianal and scroto-femoral regions rather as secondary (reactive) than primary responds to poor condition of denture and hygiene.

In addition, in JHF it is rather difficult to differ the histologically sclerotizing fibroma from an older tumor. After surgical removal of these tumors and nodules, they did not recur with proper hygiene.

At least, clear-cell acanthoma was found by chance. The tumor of 1.5 cm in size was removed after its regression within JHF was diagnosed. Its histological and histochemical picture showed a typical epithelial changes (12).

This study was supported by a grant VEGA N. 1/8150/01

REFERENCES

1. Aldred MJ, Crawford PJ. Juvenile hyaline fibromatosis. *Oral Surg Med* 1987; 63: 71-77.
2. Bedford ChD, Sills JA, Sommelet-Olive D, Boman F, Beltramo F, Cornu G. Juvenile hyaline fibromatosis: a report of two severe cases. *J Pediat* 1991; 119: 404-410.
3. Camarasa JG, Moreno A. Juvenile hyaline fibromatosis. *J Dermatol* 1986; 16: 881-883.
4. Drescher E, Woyke S, Markiewitz C. Juvenile fibromatosis in siblings (fibromatosis hyalina multiplex juvenilis). *J Pediat Surg* 1967; 26: 427-430.

5. Fayad MN, Yacoub A, Sallman S, Khudz A, der Kaloustian VM. Juvenile hyaline fibromatosis: two new patients and review of the literature. *Am J Med Genet* 1987; 26: 123–131.
6. Finlay AY, Ferguson SD, Holt PJA. Juvenile hyaline fibromatosis. *Brit J Dermatol* 1983; 218: 609–616.
7. Glover MT, Lake BD, Atherton DJ. Infantile systemic hyalinosis: newly recognized disorder of collagen. *Pediatrics* 1991; 1987: 228–234.
8. Chitale AR, Murthy AK, Maniar JK. Juvenile hyaline fibromatosis. *Ultrastruc Pathol* 1987; 11: 771–775.
9. Ishikawa H, Maeda H, Takamatsu H, Saito Y. Systemic hyalinosis (juvenile hyaline fibromatosis): ultrastructura of the hyaline with particular reference to the cross-banded structure. *Arch Dermatol* 1979; 265:195–206.
10. Kitano Y. Juvenile hyaline fibromatosis. *Arch Dermatol* 1976; 112: 86–88.
11. Kozlowski K, Beighton P. Editors. *Gamut index of skeletal dysplasias*. London: Springer Verlag, 1995.
12. McKee PH. Editor. *Pathology of the skin*. London: Mosby –Wolfe, 1996.
13. Murray J. On three peculiar cases of mulluscum fibrosum in children. *Med Chir Trans* 1873; 38: 235–253.
14. Novice FM, Collison DW, Burgdorf WHC, Esterly NB. Editors. *Handbook of genetic skin disorders*. Philadelphia: WB Saunders Comp, 1994.
15. Poretic S, Poretic B, Fischer-Herman M, Adamčič M. A unique form of mesenchymal dysplasia. *Brit J Dermatol* 1962; 74: 8–19.
16. Puzas JE, Miller MD, Rosier RN. Pathologic bone formation. *Clin Orthop Relea Res* 1989; 245: 269–281.
17. Quintal D, Jacksom R. Juvenile hyaline fibromatosis: a 15-year follow-up. *Arch Dermatol* 1985; 121: 1062–1063.
18. Remberger K, Krieg T, Kunze D, Weinmann HM, Hubner G. Fibromatosis hyalinica multiplex (juvenile hyaline fibromatosis). *Cancer* 1985; 56: 914–924.
19. Seifert G. Editor. *Morphological tumor markers*. Berlin: Springer-Verlag, 1987.
20. Schaller M, Stengel-Rutkowski S, Sollberg S, Kind P. Juvenile hyaline fibromatose. *Hautarzt* 1997; 47: 235–257.

Received: April, 22, 2002-08-28

Accepted: June, 26, 2002

TUMOURS OF THE BRACHIAL PLEXUS

VIKTOR MATEJČÍK

Neurosurgical Clinic, Comenius University, Medical Faculty, Bratislava, Slovak Republic

Abstract

Starting point: We are presenting the results of the operations of 5 patients to whom 5 tumours of the neural sheaths of the brachial plexus were surgically removed with a micro-technique within a period of 11 years, from 1990 till 2001.

Methods: 3 neurofibromas and 2 schwannoms were removed in 5 patients. Each tumour was originally from the lower trunk. All of the three schwannoms had an intra-spinal spread compared to the schwannoms.

We did not encounter any malignant neural sheaths tumours neither any other tumor, benign or metastatic malignant, that did not have an origin in the neural sheaths, which would press on or infiltrate the plexus.

We have evaluated the results according to a Donner's (1) classification of the motoric and sensitive functions.

Results: The motoric functions have improved or remained unchanged in 3 patients (60 %). The results were great in case of schwannoms. The motoric functions have improved in 2 patients with neurofibromas.

Conclusion: The patients should be surgically treated on time, till the tumours don't reach a greater volume and till there is no neurological deficit. This should be performed in a workplace dealing with the problems of peripheral nerves.

Key words: brachial plexus, schwannom, neurofibroma.

INTRODUCTION

Tumours of the neural sheaths of the brachial plexus are not common. There are only few works concerning the surgical treatment (2, 3). Most neurosurgeons encounter only a few during a lifelong practise.

Kline published a first extensive series in 1983 (2). He has described 23 tumours of the brachial plexus, 17 of which had an origin in the neural sheaths. The surgical treatment of these tumours requires exact and perfect understanding of the pathological variations. Each element of the plexus, which is in a close relation with the tumour, has to be identified. This work is presenting experiences with a surgical treatment of the neural sheaths tumours of the brachial plexus.

METHODS

We have surgically treated 5 patients with tumours of the brachial plexus in the Neurosurgery Clinics in Bratislava from 1990 till 2001. There were 3 patients with neurofibromas and 2 patients with schwannoms of the brachial plexus.

Tumours with an intra-spinal origin were not included to this study. All of the patients were completely neurologically examined; they underwent a pre- and post-operation examination controlling the presence or absence of spontaneous local or evoked pain, weakness or tingling. The evaluation of the results proceeded according to a five-degree Donner's (1) classification of the motoric and sensitive functions from the year 1994 (Table 1).

The tumours were completely removed in all patients using a micro-surgical technique. The anaesthesia that would use means causing relaxation of muscles was not used and it was therefore possible to identify the motoric fascicles using a simple stimulation. A per-operation stimulation and a record of NAP (nerve action potentials) during an EMG provide data that let us sacrifice the fascicles entering and leaving the tumours when they are not functional. This enables to remove the whole mass of the tumour entirely.

Schwannoms of the plexus (2) were removed using a front approach – 1 case, or using a sub-capsular approach. In cases, where a front and a rear approach had to be used – in patients with neurofibromas – the extra-spinal part of the tumour was removed in a co-operation with a thoracic surgeon.

Address for correspondence:

Viktor Matejčík, MD, CSc. Neurosurgical Clinic, Comenius University, Medical Faculty, Limbová 5, 833 05 Bratislava
Phone: +421- 2-5954 2532, fax: +421-2-5954 3532

Table 1: Neural sheath tumours of major nerves

Muscle strength and sensory grading system

Grade	Evaluation	Description
individual muscle grades		
0	absent	no contraction
1	poor	trace contraction
2	fair	movement against gravity only
3	moderate	movement against gravity and some (mild) resistance
4	good	movement against moderate resistance
5	excellent	movement against maximal resistance
sensory grades		
0	absent	no response to touch, pinprick, or pressure
1	bad	testing gives hyperesthesia or paresthesia; deep pain recovery in autonomous zones
2	poor	sensory response sufficient for grip and slow protection; sensory stimuli mislocalized with overresponse
3	moderate	response to touch and pinprick in autonomous zone; sensation mislocalized and not normal with some overresponse
4	good	response to touch and pinprick in autonomous zones; response localized but not normal; no overresponse
5	excellent	normal response to touch and pinprick in entire field including autonomous zones

Table 2: Pre and post-operation motoric degree in patients with neural sheaths tumours of the brachial plexus.

Postoperation motoric degree	Pre-operation motoric degree						
	5	4	3	2	1	0	TOTAL
5	1	-	-	-	-	-	1
4	-	2	-	1	-	-	1/1
3	-	-	-	-	-	-	-
2	-	-	-	-	-	-	0/2
1	-	1	1	-	-	-	-
0	-	-	-	-	-	-	-
TOTAL	1	3	1	-	-	-	

* the number in the denominator means the number of neurofibromas

The first step of the operation was an isolation and an identification of the adjacent elements to prevent a possible damage. A tumour reduction was performed in 2 cases in order to simplify the dissection. 2 patients underwent a biopsy.

Imaging examinations – MRI and CT scan – were performed in all patients.

RESULTS

The characteristic feature of schwannoms in both cases is a poor neurological symptomatology. The results of a surgical removal of schwannoms of the brachial plexus were great, there was no worsening compared to the pre-operation condition (Table 2). The post-operation condition has improved in one patient; the condition of the other remained unchanged.

The results of the operations of the neurofibromas of the plexus were less satisfactory. The neurological finding has worsened in two cases out of three.

Pain was present in any case. The Tinnel’s sign was present in patients with neurofibromas.

DISCUSSION

The results of the surgical treatment depended on the size and type of the tumour. The results were better in case of schwannomas and in case of neural sheaths tumours of smaller size.

We have used a classification according to Russell and Rubinstein (4), which differentiates two basic forms of the neural sheaths tumours: schwannomas and neurofibromas.

- schwannomas: 1) solitary
2) multiple (Von Recklinghausen's disease – VRD)
3) malignant
- neurofibromas: 1) solitary
2) multiple (Von Recklinghausen's disease – VRD)
3) malignant

Schwannomas (neurilemmomas, neurinomas) are benign, soft, slowly growing tumours that do not adhere to the skin or muscle. The average age of the patients was 43 years. The average size was 80 mm. The average period since they appeared till the operation was 2 years.

Neurofibromas of the plexus were oval, whitish-yellow, avascular and fusiform structures. The average age of the patients was 29 years; the average size was 50 mm. The average period since they appeared till the operation was 2 years.

First sign was a palpable tumor mass with a small or no neurological deficit. Tumours with minimal pre-operation symptoms and signs were successfully removed without a greater neurological deficit. Our results are comparable with the results in the literature (1, 5, 6).

The decision to operate is generally based on an expected improvement of the condition. Tumours of the neural sheaths have occurred in young and middle age. They were associated with haemangiomas of the vertebrae of the spine in three cases.

An EMG examination is able to provide an evidence of a neural lesion if it shows a retardation or a conduction block in the nerve. If there are only few neural fibres impaired, the EMG examination may be normal (1, 7).

CT scan and MRI examinations are efficient in the diagnostics of tumours of the plexus and in the verification of the cystic changes that often accompany these tumours.

MRI is able to show reliably not only the tumour and its capsule, but also nerves, from which the tumour grows.

We have not encountered malignant change or a recurrence.

Conclusion: We have observed better results in case of schwannomas and the probability of a morphological damage of the surrounding, continually running fascicles in benign schwannomas is smaller and they can be treated better with a micro-surgical technique. Neurofibromas more often originate in the motoric fascicle or fascicles compared to schwannomas, which tend to grow from the sheaths of sensitive nerves.

In general, it is possible to say that if neurofibromas are operated early in their development, there are less fascicles included and the dissection would be easier compared to large and older lesions.

Tumours with minimal pre-operation symptoms and signs were successfully removed without a greater neurological deficit.

REFERENCES

1. Donner TR, Voorhies RM, Kline DG. Neural Sheath Tumours of Major Nerves. *J Neurosurg* 1994; 81: 362-73.
2. Kline DG, Judice DJ. Operative Management of Selected Brachial Plexus Lesions. *J Neurosurg* 1983; 58: 631-49.
3. Lusk MD, Kline DG, Garcia CA. Tumour of the Brachial Plexus. *Neurosurgery* 1987; 21: 439-53.
4. Russel DS, Rubinstein LJ. Tumours of the nervous system. 4th Edition, Baltimore: Wiliams & Wilkins, 1977.
5. Artico M, Cervoni L, Wierzbicki V. Benign Neural Sheath Tumours of Major Nerves: Characteristics in 119 Surgical Cases. *Acta Neurochir (Wien)* 1997; 139: 1108-16.
6. Oberle J, Kahamba J, Richter HB. Peripheral Nerve Schwannomas – an Analysis of 16 Patients. *Acta Neurochir (Wien)* 1977; 139: 949-53.
7. Horak E, Szentirmay Z, Sugar I. Pathologic Features of Nerve Sheath Tumours with to Prognostic Signs. *Cancer* 1983; 51: 1159-67.

Instructions to authors for manuscripts submitted to ACTA MEDICA MARTINIANA

Journal Acta Medica Martiniana (AMM) publishes original papers of high quality from medical and biomedical sciences and from nursery, which have not been published yet, and will not be submitted for publication elsewhere. The papers are published in English, non-native English authors are responsible for the translation. The AMM is open access journal in print and online versions (<http://www.jfmed.uniba.sk>).

The Editorial Board of AMM requires the treatments of manuscripts in accordance with uniform requirements of biomedical journal editors (Vancouver, 1978 with the revisions in 1997 and 2000): Uniform Requirements for Manuscripts Submitted to Biomedical Journals:

<http://www.icmje.org/index.html>

Original papers in extenso should not exceed 15 pages (including references) and 5 figures or tables or their combination. The manuscript has to be written double-spaced (30 lines and maximum 60 keystrokes in a line per page) in the standard structure:

1. *The title page* (separately) should have the title of the article, full names of the authors, the name of department(s) or institution(s), full address of the corresponding author (including the phone, fax number and e-mail, if applicable).

2. *Abstract* (separately) in the extent of 1 standard page. Three to five key words are appended at the end of the abstract page.

3. *Introduction* should introduce into the problem and state the purpose of the article.

4. *Methods* should be complete to allow other workers to reproduce the results. Describe statistical methods. Indicate whether the procedure followed was in accordance with the ethical standards and with the Helsinki Declaration from 1975 as revised on 1983.

5. *Results*: Present your results in logical sequence in the text, tables and illustrations.

6. *Discussion*: Emphasize the new and important aspects of the study, link the conclusions with the presented goals of the study, relate the results to other relevant studies with a short summary of results at the end.

7. *References*: All publication cited in the text should be presented in references. References have to be numbered consecutively in the order in which they are first mentioned within the text. Identify references in the text by Arabic numerals in parantheses. Use abbreviations of the journals according to Index Medicus (List of Journal Indexed in Index Medicus, <http://www.nlm.nih.gov>).

Examples as follow (other examples are included on the web page being mentioned):

Article in Journal: Vega KJ, Puna I, Krevsky B. Heart transplantation is associated with risk for pancreatobiliary disease. Ann Intern Med 1996; 124 (11): 980-3.

Books and other Monographs: Bond J. Ageing of spy. New York: Churchill Livingstone? 1999.

Chapter in a book: Phillips SJ, Whisnant JP. Hypertension and stroke. In: Laragh JH, Brenner BM, editors. Hypertension: pathophysiology, diagnosis, and management. 2nd ed. New York: Raven Press? 2001. p. 465-78.

Illustrations and tables: Letters, numbers and symbols should be sufficient size that when reduced for publication each item will still be legible. Type legends for illustrations on a separate page. Each table has to be on a separate page too. Place explanatory matter in footnotes. Vertical rules should be omitted. Figures and tables should be numbered consecutively according to the order in which they have been first cited in text.

Units of Measurement and Symbols: Measurements of length, height, weight, and volume should be reported in metric units. Temperatures should be given in degrees Celsius, blood pressure in millimeters of mercury. All other measurements should be reported in the terms of the International System of Units (SI).

One complete original manuscript with one set of high-quality prints of the figures and two complete copies, each containing tables and copies of the figures, must be submitted to the address of the Editorial Board Office.

All manuscripts will be peer-reviewed anonymously by external experts pursuant to the standard evaluation criteria. Based on the review opinions, the Editorial Board will decide, whether the paper is to be included in the journal.

After a manuscript is accepted for publication, one hardcopy of the final revised, accepted version of the paper must be submitted along with the same version on a 3.5-in. diskette. Text files should be saved as word processing document using Microsoft Word. The manuscript has to include an attachment as follows: *The work is an original, which has not been published in its full extent yet and will not be submitted elsewhere before a decision has been taken as to its acceptability by Acta Medica Martiniana. In consideration of the acceptance of the above work for publication, I do hereby assign and transfer to the publisher the copyright including display of the article in electronic form on web (open access).*

Publication of articles is free of charge.

AMM EDITORIAL BOARD
Dept. of Physiology Jessenius Medical Faculty
Comenius University
Mala Hora Str. N. 4
037 54 MARTIN
SLOVAKIA